
Cosmetic Case Report

Cyst Formation after Fat Injection

Apostolos D. Mandrekas, M.D., George J. Zambacos, M.D., and Chris Kittas, M.D.

Athens, Greece

Fat transplantation to correct deformities was advocated more than a hundred years ago by Neuben,¹ but it was Lexer who first documented and published his results.² After the introduction of liposuction by Illouz in 1977, fat transplantation was rediscovered, and the term liposculpture was coined by Fournier² to describe a procedure by which adipose tissue was removed with liposuction and selectively injected to areas with contour irregularities.

We have been using suction-assisted lipectomy for the past 13 years, and we have used the aspirated fat to correct contour irregularities, by injection, on several occasions. We describe a case in which, after autologous fat injection in a woman after liposuction, a cyst developed containing pearl-like fat lobules.

CASE REPORT

A 44-year-old woman, who had undergone inner thigh lifting two years before her visit, came to our center to have liposuction of the trochanteric and inner knee areas and to correct a contour anomaly (depression secondary to her previous operation) at her left groin.

The operation was performed under local anesthesia, using the tumescent technique, and 300 cc of adipose tissue was removed from each trochanteric area and 100 cc from each knee. The liposuction was performed with a 3-mm cannula using a 60-cc syringe. The aspirated adipose tissue was placed in a container to allow for settling of excess fluid. The liquid was discarded, and the adipose tissue was rinsed with normal saline and allowed to set again. The fluid was discarded again, and about 40 cc of adipose tissue were injected to the patient's left groin to correct the depression.

Approximately 3 months postoperatively, the patient returned to the office complaining of a palpable, mobile mass on her left groin, at the site of fat injection. Two months later, the patient was reoperated on under local anesthesia, and a large cyst (3 × 10 cm) was removed, which was full of pearl-like fat lobules (Figs. 1 and 2). Histologic examination showed mostly mature fat cells, which in some areas seemed to coalesce and form small and occasionally larger fatty globules.

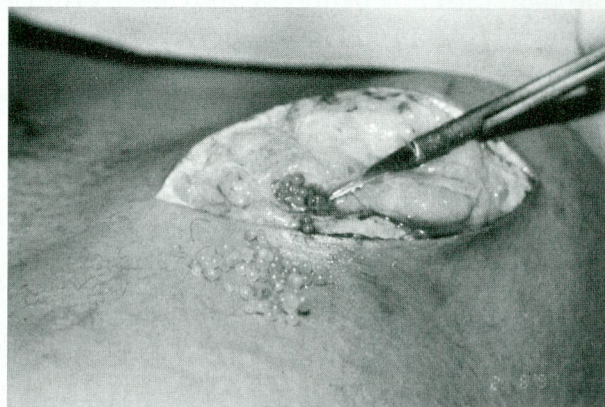


FIG. 1. Large cyst containing pearl-like fat lobules at the patient's left groin after fat injection for aesthetic reasons.

DISCUSSION

Since 1985, when the idea of and the term liposculpture were introduced, this procedure has proved to be safe and efficient for the correction of contour deformities.² Several refinements have been introduced over the years, including using small-caliber cannulas (3 to 4 mm), so the transplanted threads of adipose tissue do not exceed 3 mm in diameter; using low negative pressure during the aspiration, to minimize mechanical distention and damage of adipocytes; observing sterile techniques during harvesting and transplantation; and rinsing the aspirated fat with normal saline.^{1,3}

Reports of complications after autologous fat transplantation describe edema, hematoma, infection, fibrosis, and development of liponecrotic cysts containing an oily fluid.⁴⁻⁷ In the case presented, the patient developed a large cyst containing mature fat cells taking the form of pearl-like globules. We could not find any similar instances in the literature.

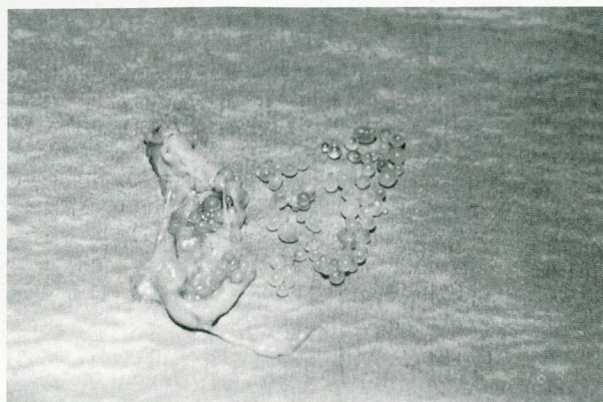


FIG. 2. The removed cyst containing pearl-like fat lobules.

SUMMARY

Autologous fat injection has been widely used during the past 20 years to correct contour anomalies. We have been using suction-assisted lipectomy for the past 13 years, and we have used the aspirated fat to correct contour irregularities on several occasions. We present the case of a 44-year-old woman who, after autologous fat transplantation to correct a contour anomaly (depression secondary to a previous operation) at her left groin, developed a large cyst containing pearl-like fat lobules. The cyst was first noticed 3 months postoperatively

and was removed under local anesthesia 5 months postoperatively. Histology confirmed that the lobules were mature fat cells.

A. D. Mandrekas, M.D.

ARTION Plastic Surgery Center
11 D. Vassiliou Street
Athens 15451, Greece

REFERENCES

1. Niechajev, I., and Sevcuk, O. Long-term results of fat transplantation: Clinical and histologic studies. *Plast. Reconstr. Surg.* 94: 496, 1994.
2. Pereira, L. H., and Radwanski, H. N. Fat grafting of the buttocks and lower limbs. *Aesthetic Plast. Surg.* 20: 409, 1996.
3. Ersek, R. A. Transplantation of purified autologous fat: A 3-year follow-up is disappointing. *Plast. Reconstr. Surg.* 87: 219, 1991.
4. Har-Shai, Y., Lindenbaum, E., Ben-Itzhak, O., and Hirshowitz, B. Large liponecrotic pseudocyst formation following cheek augmentation by fat injection. *Aesthetic Plast. Surg.* 20: 417, 1996.
5. Maillard, G. F. Liponecrotic cysts after augmentation mammoplasty with fat injections. *Aesthetic Plast. Surg.* 18: 405, 1994.
6. Chajchir, A. Fat injection: Long-term follow-up. *Aesthetic Plast. Surg.* 20: 291, 1996.
7. Chajchir, A., and Benzaquen, I. Fat-grafting for soft-tissue augmentation. *Plast. Reconstr. Surg.* 84: 921, 1989.