

Treatment of bilateral severe eyelid burns with skin grafts: an odyssey

Apostolos D. Mandrekas*, George J. Zambacos, Anastasios Anastasopoulos

Artion Plastic Surgery Center, 11 D. Vassiliou Street, N. Psychiko, Athens 15451, Greece

Accepted 17 April 2001

Abstract

Eyelid burns occur in about 10% of thermal injuries and pose a considerable challenge for the reconstructive surgeon. A consensus on a treatment regime has not been reached and plastic surgeons are divided on the subject. A case of severe bilateral eyelid burns was treated with full- and split-thickness skin grafts. The patient was first operated at 2 years post-injury, and a total of 5 operations in 5 years were necessary to address recurrent ectropion of both upper and lower eyelids. © 2002 Elsevier Science Ltd and ISBN. All rights reserved.

Keywords: Burns; Eyelids; Skin grafts

1. Introduction

Burns are devastating injuries scarring patients, both physically and psychologically, for life. This stands particularly true for facial burns. Eyelid burns occur in less than 10% of all thermal injuries, but are very common in patients with burns involving the face [1–3].

Reconstruction of the eyelids following burn injuries has been the object of plastic surgeons since the earliest days of reconstructive surgery [4], yet a uniform treatment regime has not been advocated and the various therapeutic options have divided plastic surgeons for several years.

In this paper we present a case of severe flame burns involving both upper and lower eyelids, bilaterally, treated with repeated skin grafting, both full and split thickness, and discuss the indications and problems associated with this therapeutic modality.

2. Case report

A 28-year male patient was involved in an industrial accident in an oil refinery in 1992, suffering over 85% deep burns. His face was not spared and both upper and lower eyelids were involved bilaterally. The patient was initially treated in a major burns center for 4 months and presented to us in 1994, 2 years post-burn, with severe cicatricial

ectropion, more pronounced on the left side, and hooding of the medial epicanthal area on both eyes (Fig. 1).

Planning of the eyelid reconstruction was particularly difficult as there was a scarcity of healthy skin to use for grafting. Our first instinct was to use full thickness grafts for both the upper and lower eyelids, because due to the severity of the burn injury, and although it was then 2 years post-burn, recurrent contracture was almost certain.

The right post-auricular and supra-clavicular regions were burned, and so a decision was made to use full thickness skin grafts from the left supra-clavicular region and the left arm and to save the post-auricular skin for a later stage of the reconstruction.

The upper and lower eyelids were released on both sides with incisions running along the lid margins, around the whole eye, down to the orbicularis (Fig. 2a,b). Z-plasties were performed on both inner canthi to address the hooding of the medial epicanthal areas.

Six months later the patient returned with bilateral cicatricial ectropion. The scars were again released surgically and both upper and lower eyelids were resurfaced with split thickness skin grafts. The patient again developed cicatricial ectropion of both lower eyelids and in another 6 months a third attempt was made, this time grafting the lower eyelids with full thickness skin grafts harvested from the left arm.

Unfortunately the patient developed further contraction (Fig. 3) and 3 years later (1998), now 4 years after the initial operation, he was operated upon for the fourth time. This time, after scar release the lower eyelids were resurfaced with full thickness skin grafts harvested from the left post-auricular region, while the upper eyelids were covered with split thickness skin grafts (Fig. 4).

* Corresponding author.

E-mail address: amandrekas@artion-plasticsurgery.com (A.D. Mandrekas).

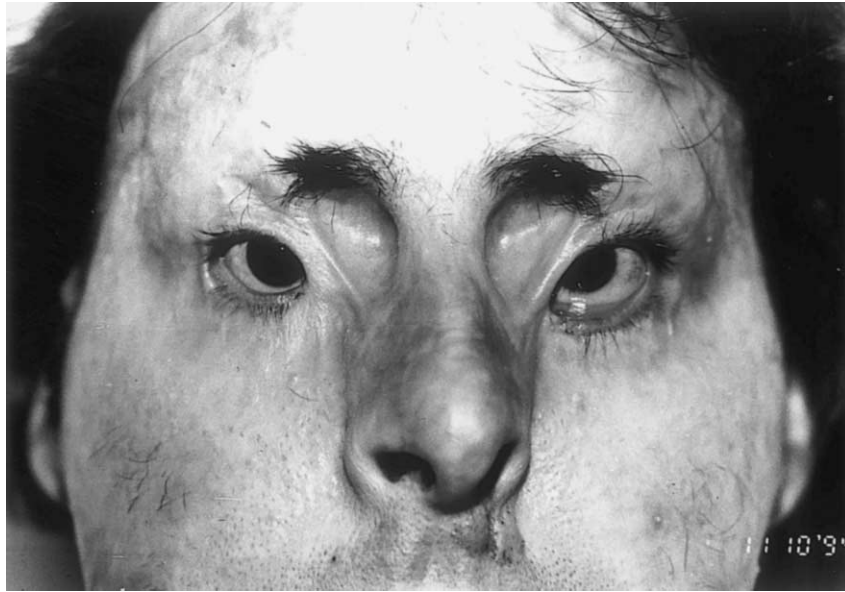

Fig. 1. Twenty-eight-year-old patient with severe cicatricial ectropion and hooding of the medial epicanthal area 2 years following deep burns.

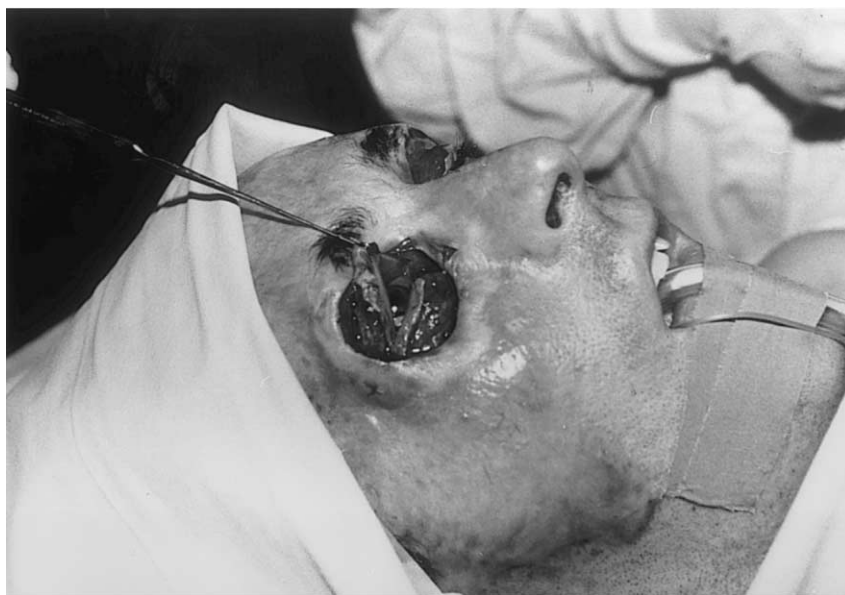One year later (November 1999—5 years after the initial operation) the patient returned with cicatricial ectropion on the left lower eyelid, and was operated upon once more (for the fifth time), this time utilising a full thickness skin graft from the left arm (Fig. 5a–c).

The grafts were fixed with a tie-over bolus dressing using foam. Graft take was 100% on all occasions.

The current state of the patient, 6 years after the initial operation and following a total of 5 operations is depicted on Fig. 6.

3. Discussion

Eyelid burns represent a most difficult problem for reconstructive surgeons. The anatomy of the eyelids, as described by Schofield in 1955 [4], accurately explains the cause for this. The lateral ends of the condensed fibrous tissue of the tarsal plates unite to form the palpebral ligaments, which anchor the eyelids in the transverse plane. In the vertical plane the tarsal plates are loosely attached to the periosteum of the orbital margin by the thin palpebral fascia. The only other



(a)

Fig. 2. Release of upper and lower eyelids down to orbicularis: (a) left lateral; (b) right lateral.

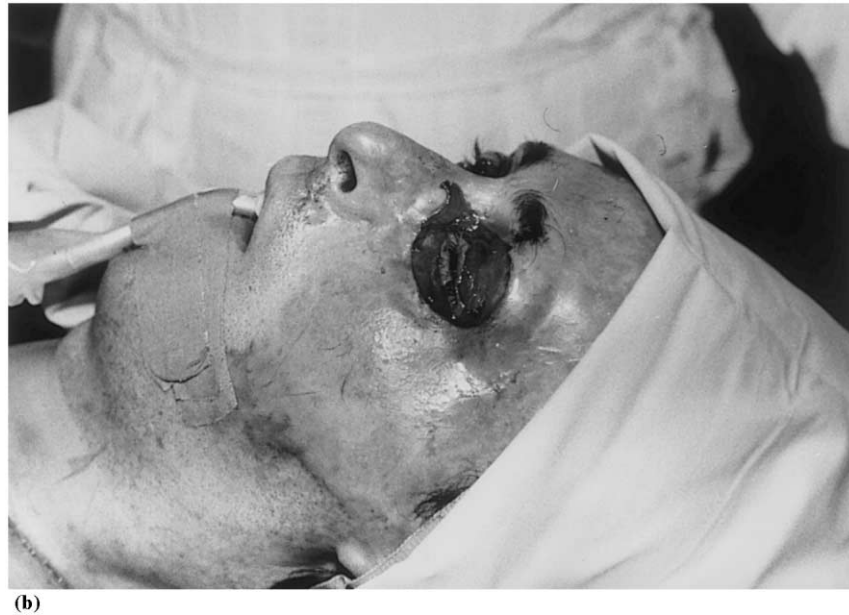

Fig. 2. (Continued).

attachment of the eyelids to the underlying skeleton is the attachment of the orbicularis muscle to the medial margin of the orbit.

Thus, burn injuries involving the eyelid tissues are totally at the mercy of the distractive forces of wound contraction and scar, the bony orbital margins being the buttresses to which they are pulled [4,5]. This was recently confirmed by Stephenson et al. [6], who showed that the peri-orbital area appeared to suffer the most contraction in relation to other grafted areas.

Cicatricial ectropion is the most common late sequela, leaving the globe, cornea and ocular conjunctiva unprotected [7,8], and is often associated with hooding over the medial epicanthal area [9,10].

Recurrent contracture of the eyelids is quite common, especially among those who have undergone the releasing procedure while the underlying scar is still active. Timing of surgical intervention, therefore, becomes the single most important factor in determining the ultimate outcome of the release [9]. Lid wound scar maturation requires 9 months or

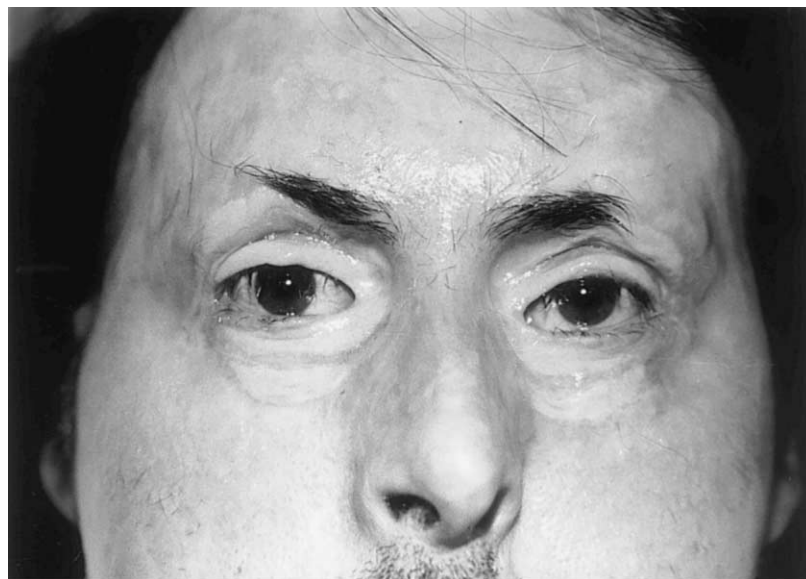

Fig. 3. Result following the third operation, 4 years after the initial operation.

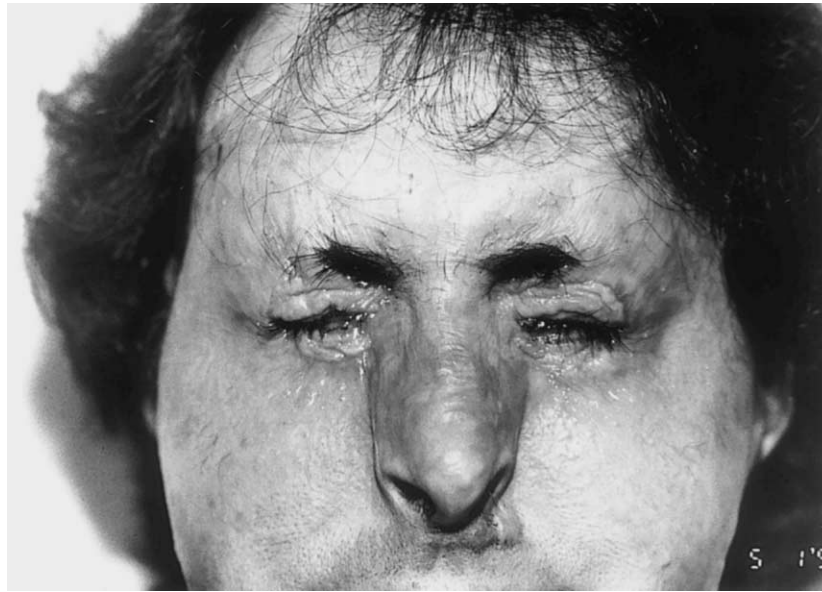

Fig. 4. Result following the fourth operation with full-thickness skin grafting of lower eyelids and split-thickness skin grafting of upper eyelids.

more and all secondary procedures should be delayed for at least that amount of time, to minimize possible recurrence [5,9,11].

The degree of contraction of a split thickness skin graft may vary considerably—it may contract to one-fourth of its original size [4]. According to Schofield [4] the thicker the graft the greater will be the number of surviving capillary plexuses and so the earlier will be the return of the grafted skin to normal and with it the earlier the development of a normal subcutaneous tissue. Brown et al. [12] showed that the capacity of a skin graft to inhibit wound contraction

is directly proportional to the amount of structurally intact dermal collagen present in the skin graft. It follows that full thickness grafts have much more dermis present and subsequently contract much less, if at all. Stephenson et al. [6] however challenged this belief, showing that even in the absence of infection full thickness skin grafts contracted by one third, while in the presence of infection the contraction was as much as 50%.

Until recently the dogma in lid reconstruction was to use split thickness grafts for the mobile upper eyelids and full thickness skin grafts for the lower lids. Full thickness skin

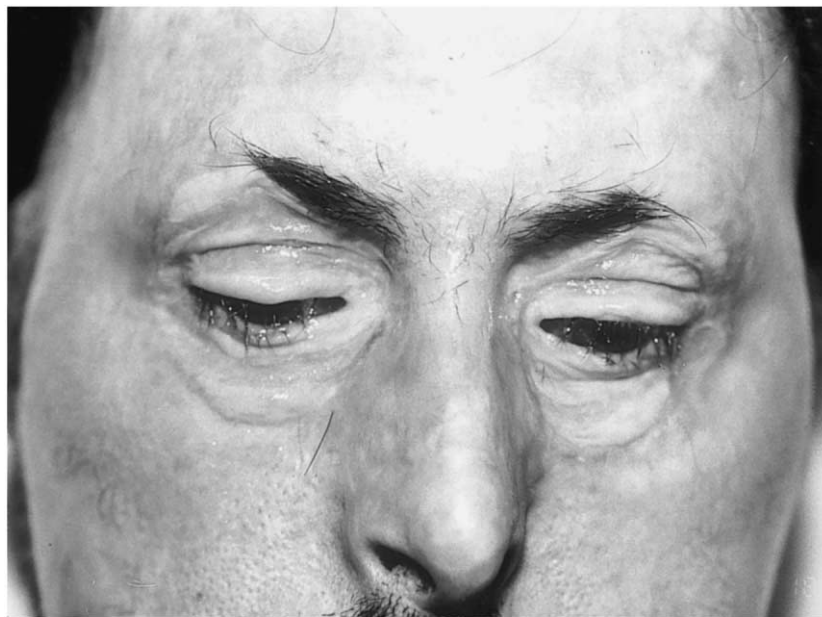

Fig. 5. Result following 5 operations in 5 years: (a) front; (b) left lateral; (c) right lateral.

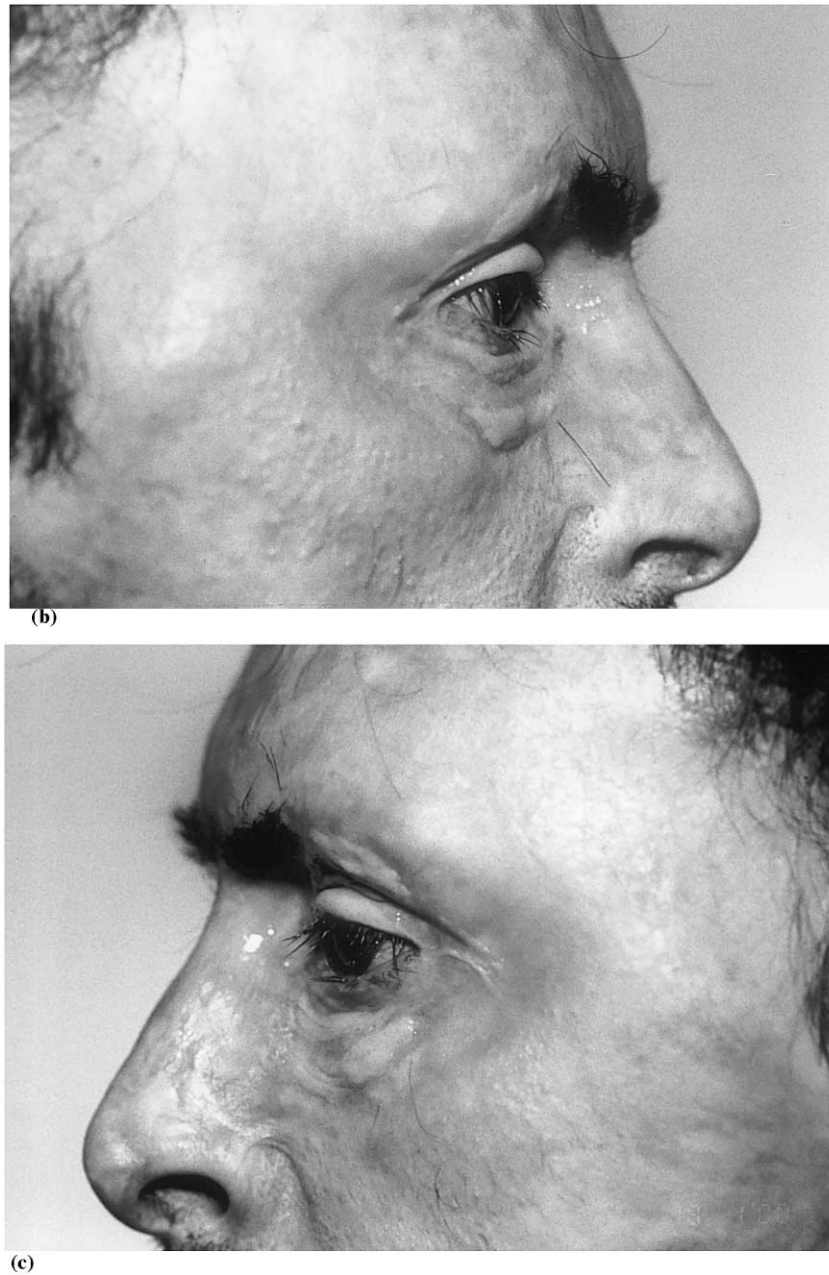


Fig. 5. (Continued).

grafts would be ideal in terms of their properties regarding contraction, but due to their lack of suppleness they were considered unsuitable for use in the upper eyelid [4,13]. A recent publication re-addressed this dogma and concluded that the use of full thickness skin grafts in both the upper and lower eyelids reduced the incidence of ectropion, without affecting function [14].

Our patient had suffered severe deep burns, amounting to over 85% body surface area (BSA), involving both upper and lower eyelids bilaterally. The available skin was scarce and due to the severity of the injury recurrent ectropion was

more than likely, although nearly 2 years had passed since the initial injury.

Although at the time of the first attempt at reconstruction full thickness skin grafting of the upper eyelids was considered taboo, we believed that ultimately this was the correct choice for both upper and lower eyelids since it would minimize recurrence. We were wrong. Our patient had to undergo five operations in 5 years, using full and split thickness skin grafts in various combinations. One could argue that release at the initial operation was inadequate as it did not extend 1.5 cm beyond the lateral canthal limit and 0.5 cm beyond

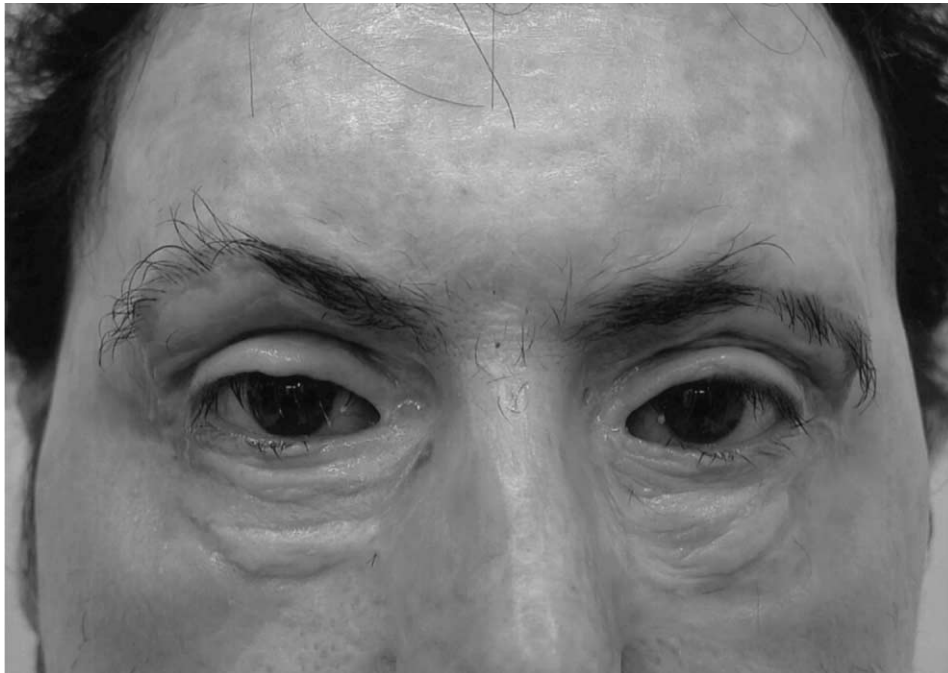

Fig. 6. Current state of the patient 6 years after the initial operation.

the medial canthal limit as recommended by many authors [9,10,15]. This was not the case however in subsequent operations where the extent of the release was well beyond the canthal limits.

Timing of the reconstruction is another very important issue. According to most studies it should be delayed for at least 9 months after the initial injury, so as to allow maturing of the scars [6,8,10]. Our first attempt was performed 2 years post-burn, when the inflammatory reaction to the thermal injury should have subsided. Apparently it had not. The scars were released down to the orbicularis muscle, and furthermore the release was extended beyond the medial and lateral canthal areas on at least three of the five operative sessions and the skin grafts were applied generously to achieve over-correction. Yet recurrence of the ectropion occurred within less than 6 months. Subsequent attempts were also unsuccessful, up to 7 years after the initial injury. Our (hopefully) last attempt was in November 1999.

Our experience with this patient somehow overturns current beliefs on eyelid reconstruction: (1) scar maturation is, apparently, not necessarily achieved within 2 or even more years of the initial injury; (2) full thickness skin grafts do not preclude contracture; and (3) a third issue noticed in our case was that upper eyelid function was not affected by the use of full thickness grafts.

4. Conclusion

Eyelid reconstruction in burned patients is far from straightforward, and repeated operations are usually the

rule instead of the exception. There are no safe time limits, nor binding aphorisms regarding the tissue used for the reconstruction. One has to individualise each case and use whatever is available (which sometimes is not much). Unfortunately, embarking on an attempt to reconstruct the severely thermally injured eyelids, is, more often than not, the beginning of a long but not always happy relationship.

References

- [1] Feldman JJ. Facial burns: the eyelids. In: McCarthy JG, editor. *Plastic surgery*, vol. 3. Philadelphia: W.B. Saunders, 1990:2210–8.
- [2] Grabosch A, Weyer F, Gruhl L, Bruck JC. Repair of the upper eyelid by means of the prepuce after severe burns. *Ann Plast Surg* 1991;26:427–30.
- [3] Barrow RE, Jeschke MG, Herndon DN. Early release of third-degree eyelid burns prevents eye injury. *Plast Reconstr Surg* 2000;105:860–3.
- [4] Schofield AL. A review of burns of the eyelids and their treatment. *Br J Plast Surg* 1955;7:67–91.
- [5] Warpeha RL. Resurfacing the burned face. *Clin Plast Surg* 1981;8:255–67.
- [6] Stephenson AJ, Griffiths RW, La Hausse-Brown TP. Patterns of contraction in human full thickness skin grafts. *Br J Plast Surg* 2000;53:397–402.
- [7] Silverstein P, Peterson HD. Treatment of eyelid deformities due to burns. *Plast Reconstr Surg* 1973;51:38–43.
- [8] Astori IP, Muller MJ, Pegg SP. Cicatricial postburn ectropion and exposure keratitis. *Burns* 1998;24:64–7.
- [9] Huang TT, Blackwell SJ, Lewis SR. Burn injuries of the eyelids. *Clin Plast Surg* 1978;5:571–81.
- [10] Sloan DF, Huang TT, Larson DL, Lewis SR. Reconstruction of eyelids and eyebrows in burned patients. *Plast Reconstr Surg* 1976;58:340–6.

- [11] McIndoe AH. Total reconstruction of the burned face. The Bradshaw Lecture 1958. *Br J Plast Surg* 1983;36:410–20.
- [12] Brown D, Garner W, Young VL. Skin grafting: dermal components in inhibition of wound contraction. *South Med J* 1990;83:789–95.
- [13] Falvey MP, Brody GS. Secondary correction of the burned eyelid deformity. *Plast Reconstr Surg* 1978;62:564–70.
- [14] Lille ST, Engrav LH, Caps MT, Orcutt JC, Mann R. Full thickness grafting of acute eyelid burns should not be considered taboo. *Plast Reconstr Surg* 1999;104:637–45.
- [15] Achauer BM, Adair SR. Acute and reconstructive management of the burned eyelid. *Clin Plast Surg* 2000;27(1):87–96.