

# Aesthetic Reconstruction of the Tuberous Breast Deformity

**Apostolos D. Mandrekas, M.D., George J. Zambacos, M.D., Anastasios Anastasopoulos, M.D.,  
Dimitrios Hapsas, M.D., Nektaria Lambrinaki, M.D., and Lydia Ioannidou-Mouzaka, M.D.**

*Athens, Greece*

The tuberous breast deformity is a rare entity affecting young women bilaterally or unilaterally. The deformity is characterized by a constricting ring at the base of the breast, which leads to deficient horizontal and vertical development of the breast with or without herniation of the breast parenchyma toward the nipple-areola complex and areola enlargement. Several methods have been put forward to correct the deformity, but most of these fail to address the issue of the constricting ring and subsequently yield results that are not aesthetically satisfactory. A new approach to the treatment of the deformity is presented, which consists of a periareolar approach and rearrangement of the inferior part of the breast parenchyma by division of the constricting ring, thus creating two breast pillars. These pillars are allowed to redrape, and in cases of volume deficiency, a silicone breast implant is placed in a subglandular pocket. The procedure is completed by a donut-type excision to address the size of the nipple-areola complex. The technique has been used on 11 patients (21 breasts) with excellent aesthetic results. (*Plast. Reconstr. Surg.* 112: 1099, 2003.)

The tuberous breast deformity is a rare entity affecting teenage women unilaterally or bilaterally.<sup>1,2</sup> Its exact incidence has not been properly investigated and remains unknown.<sup>1,2</sup> Nonetheless, this deformity produces much psychological morbidity and presents a reconstructive challenge for the plastic surgeon.

The tuberous breast deformity was first described in 1976 by Rees and Aston<sup>3</sup> and was so named because “it resembled the shape of a tuberous plant root.” Unfortunately, in that same, seminal article, the authors described another “similar,” as they said, deformity: the “tubular breast.” Since then, several articles have been published on the subject, each using its own nomenclature, thereby producing much confusion among plastic surgeons.<sup>4</sup>

Tuberous breasts,<sup>3,5</sup> tubular breasts,<sup>3,5,6</sup> Snoopy breasts,<sup>5-9</sup> herniated areolar complex,<sup>5,6,9,10</sup> domed nipple,<sup>9,10</sup> nipple breast,<sup>9,11</sup> constricted breast,<sup>6</sup> lower-pole hypoplasia,<sup>5,6</sup> and narrow-based breast<sup>5,6</sup> are some of the names used to describe this deformity or the so-called new deformities that, under careful inspection, are no different from the original one described by Rees and Aston.

The essence of the matter remains that there is deficiency in the vertical and/or horizontal dimensions of the breast, usually characterized by underdevelopment of the breast and often herniation of breast tissue into the areola with hypertrophy of the areola.<sup>1-3,6,8-10,12-14</sup>

In our view, the reason for the confusion in the literature lies in the lack of understanding of the anatomical/histopathological abnormality underlying the deformity.

## ANATOMY AND EMBRYOLOGY

Embryologically, the breast comes from the mammary ridge, which develops in utero from the ectoderm during the fifth week.<sup>15,16</sup> Shortly after its formation (seventh to eighth week), most parts of this ridge disappear, except for a small portion in the thoracic region that persists and penetrates the underlying mesenchyme (10 to 14 weeks).<sup>16</sup> Further differentiation and development of the breast occurs during the intrauterine life and is completed by the time of birth, after which essentially no further development occurs until puberty.<sup>15</sup>

The next series of steps in the development of the breast are activated at puberty in the female. These steps consist of growth of the

From the “Artion” Plastic Surgery Center. Received for publication September 18, 2002; revised January 8, 2003.

DOI: 10.1097/01.PRS.0000076502.37081.28

mammary tissue beneath the areola with enlargement of the areola, until the age of 15 to 16, when the breast assumes its familiar shape.<sup>15-17</sup>

As a result of the ectodermal origin of the breast and its invagination into the underlying mesenchyme, the breast tissue is contained within a fascial envelope, the superficial fascia.<sup>15,16,18</sup> This superficial fascia is continuous with the superficial abdominal fascia of Camper and consists of two layers: the superficial layer of the superficial fascia, which is the outer layer covering the breast parenchyma, and the deep layer of the superficial fascia, which forms the posterior boundary of the breast parenchyma and lies on the deep fascia of the pectoralis major and serratus anterior muscles.<sup>15,16,18</sup> The deep layer of the superficial fascia is penetrated by fibrous attachments called suspensory ligaments of Cooper, which join the two layers of the superficial fascia and extend to the dermis of the overlying skin and the deep pectoral fascia.<sup>15,16,18</sup>

A critical point in the understanding of the tuberous breast deformity is the fact that the superficial layer of the superficial fascia is absent in the area underneath the areola, as can easily be demonstrated by the invagination of the mammary bud in the mesenchyme.<sup>17</sup>

Clinical experience has shown us and other authors<sup>2,19</sup> that, in cases of tuberous breasts, there is a constricting fibrous ring at the level of the periphery of the nipple-areola complex that inhibits the normal development of the breast. This constricting ring of fibrous tissue is denser at the lower part of the breast and does not allow the developing breast parenchyma to expand during puberty. Our own understanding is that this ring represents a thickening of the superficial fascia, as described earlier. Perhaps the two layers of this fascia join at a higher level than usual, or it could be that the suspensory ligaments are thicker and more dense.<sup>5</sup>

The result in either case is that the developing breast cannot expand inferiorly,<sup>5</sup> and due to the fact that there is no superficial layer of the superficial fascia under the areola, the breast parenchyma herniates toward the nipple-areola complex. The severity of the deformity depends on the severity of the malformation of the superficial fascia and ranges from slight underdevelopment of the inferior medial quadrant of the breast with near-normal breast volume to major hypoplasia of all four quadrants with various degrees of herniation of

the breast parenchyma toward the areola, as already described in several classifications submitted over the years.<sup>5,6,14,20</sup> We have adopted the classification of Grolleau et al.,<sup>5</sup> according to which deficiency of the lower medial quadrant is type I, deficiency of both lower quadrants is type II, and deficiency of all four quadrants is type III.

On the basis of this understanding of the anatomical basis of the deformity, we were able to develop our own protocol for the treatment of the tuberous breast deformity, which comprises correction of the anatomical malformation(s).

#### PATIENTS AND METHODS

Eleven patients were treated with our technique in the last 5 years; 10 patients had bilateral deformity and one patient had unilateral deformity (21 breasts) (Table I).

The procedure begins with the preoperative marking of the new inframammary fold, with the patient in the standing and the supine positions, by projection of the contralateral breast in unilateral cases, or by using the sixth rib as a landmark in bilateral cases.<sup>8</sup> A periareolar donut-type skin excision (de-epithelialization) is performed to reduce the areola to the desired size, usually 4 to 4.5 cm in diameter (Fig. 1, *above, left*). The skin of the inferior half of the breast is undermined down to the pectoralis fascia with sharp dissection (Fig. 1, *above, center*). Once the lower border of the breast parenchyma is reached, the dissection continues farther down toward the new inframammary fold, and then upward, behind the breast, along the natural plane between the deep layer of the superficial fascia and the deep fascia bluntly (Fig. 1, *above, right*). The breast parenchyma is dissected off the deep pectoral fascia, leaving only the superior part of the breast attached. The dissection is also extended laterally and medially, and the breast parenchyma is exteriorized through the periareolar opening. The exteriorized inferior half of the breast is transected with a vertical incision along the middle (Fig. 1, *below, left*, and Fig. 2). The constricting fibrous ring is thus divided, and two breast pillars are created that allow the breast parenchyma to redrape, assuming a more natural shape. If the pillars are short, they are just loosely approximated using absorbable sutures (4-0 Vicryl; Ethicon, Somerville, N.J.). If the two pillars are long, as is the

TABLE I  
Patients, Methods, and Outcomes

Case	Patient Age (yr)	Breast Pathology		Implants		Outcomes			Notes	Figure
		Left	Right	Left	Right	Surgical Team		Patient		
						Correction	Symmetry	Satisfaction		
1	46	Type II	Type II	275 cc	275 cc	3	3	3	Previous failed attempt with 110 cc augmentation	3
2	31	Type II	Type II	225 cc	225 cc	3	3	3		
3	30	Type II	Type II	225 cc	225 cc	3	3	3	Size increase with pregnancy	4
4	28	Type II	Type II	250 cc	250 cc	3	3	3		
5	22	Type II	Type II	No	No	3	3	3		5
6	17	Type III	Type II	300 cc	200 cc	3	2	3		6
7	32	Type II	Type II	No	No	3	3	3		
8	23	Class A ptosis	Type II	Inferior pedicle reduction	No	3	3	3		7
9	34	Type II	Type II	250 cc	250 cc	3	3	3		
10	27	Type II	Type II	225 cc	225 cc	3	3	3		
11	21	Type III	Type I	225 cc	No	3	2	3		8

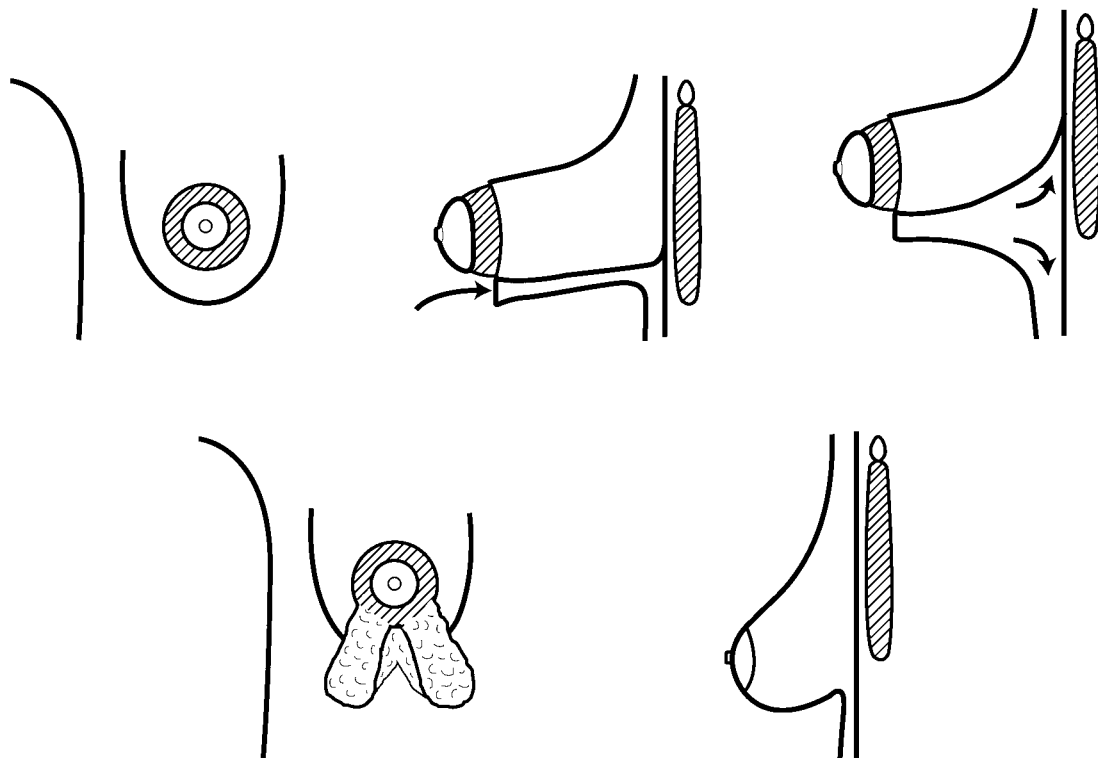


FIG. 1. Technique: (Above, left) Periareolar donut-type skin excision. (Above, center) The skin of the inferior half of the breast is undermined down to the pectoralis fascia with sharp dissection. (Above, right) The dissection continues further down toward the new inframammary fold, and then upward, behind the breast with blunt dissection. The breast parenchyma is dissected off the deep pectoral fascia, leaving only the superior part of the breast attached. (Below, left) The breast parenchyma is exteriorized through the periareolar opening. The exteriorized inferior half of the breast is transected with a vertical incision along the middle. (Below, right) The resulting breast has a normal-sized areola, a natural shape, a volume matching the contralateral breast, and no evidence of the “double-bubble” deformity.

case in Figure 2, then the proximal parts are again approximated by using absorbable sutures, and the distal parts are either allowed to redrape

freely or are folded over each other like a double-breasted jacket to create added volume in the inferior portion of the breast.

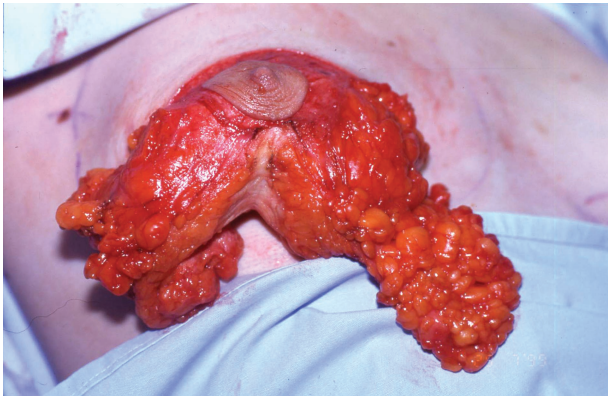


FIG. 2. Transection of the constricting ring and creation of breast pillars.

If necessary, a silicone breast implant is placed behind the breast parenchyma, with particular care taken so that the pillars cover the implant in its entirety. The decision to use a breast implant is usually made at the preoperative consultation in which doctor and pa-

tient discuss whether additional volume will be required. Round textured silicone gel implants are usually used. The periareolar incision is sutured in layers with deep subcutaneous and intradermal sutures using long-lasting dissolvable material (4-0 polydioxanone suture or Monocryl; Ethicon). So far, with a maximum follow-up of 4 years, we have not had any problems with stretching of the periareolar scar.

### RESULTS

The resulting breast has a normal-sized areola, a natural shape, a volume matching the contralateral breast, and no evidence of the "double-bubble" deformity (Fig. 1, *below, right*, and Figs. 3 through 8).

The outcome measures used in this group of patients were correction of the deformity, breast symmetry, and patient satisfaction. An analogue scale with a range from 1 to 3 was used for each of the three parameters men-

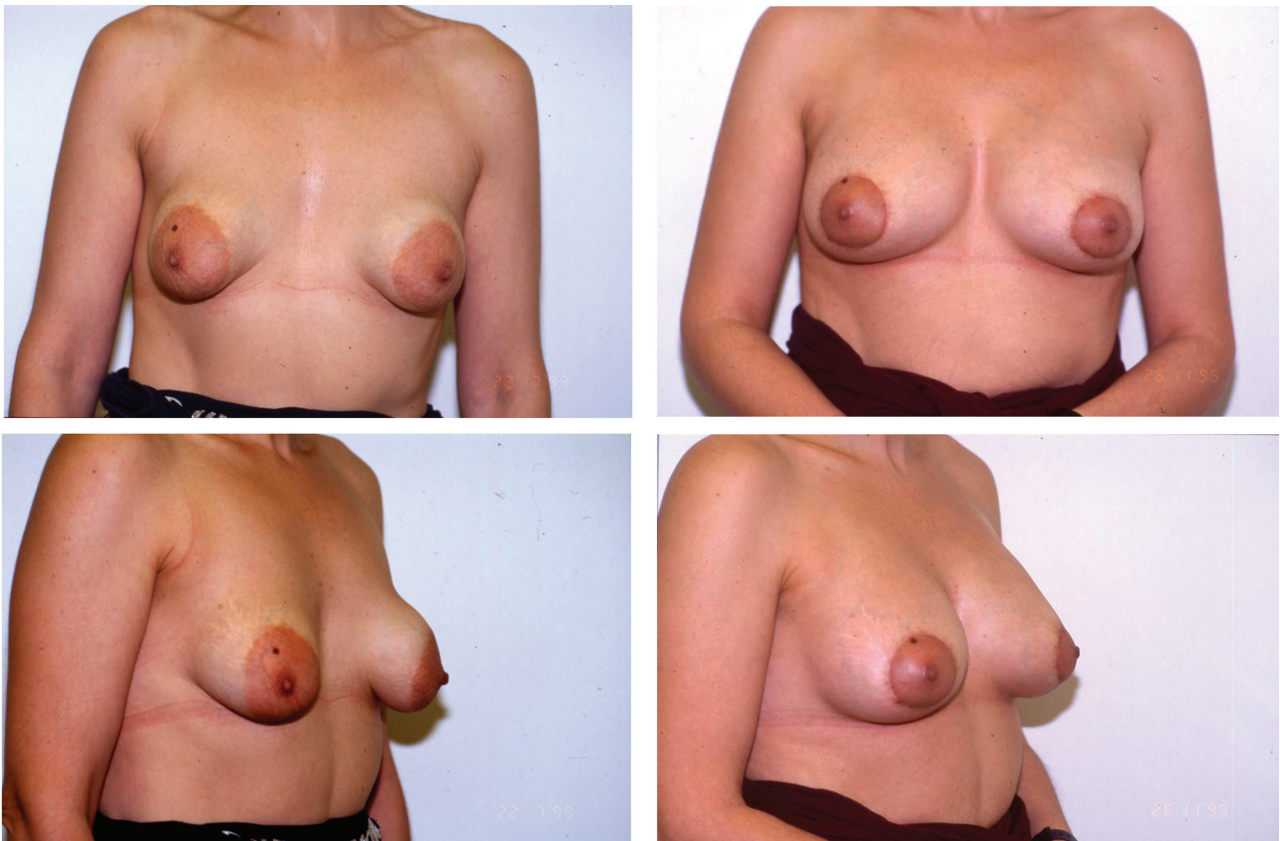


FIG. 3. Forty-six-year-old patient (case 1) with a previous failed attempt to reconstruct a bilateral type II tuberosity breast deformity with subglandular placement of 110-cc silicone breast implants. Both breasts are constricted in both the vertical and horizontal axis, with herniation of the breast parenchyma toward the nipple-areola complex and increased size of the areola. A periareolar donut-type excision was followed by removal of the implants, capsulectomy, dissection of the breast parenchyma, division of the fibrous ring with development of two pillars, and placement of 275-cc implants in the same subglandular pocket. Shown are front and left oblique views, preoperatively and 4 months postoperatively.



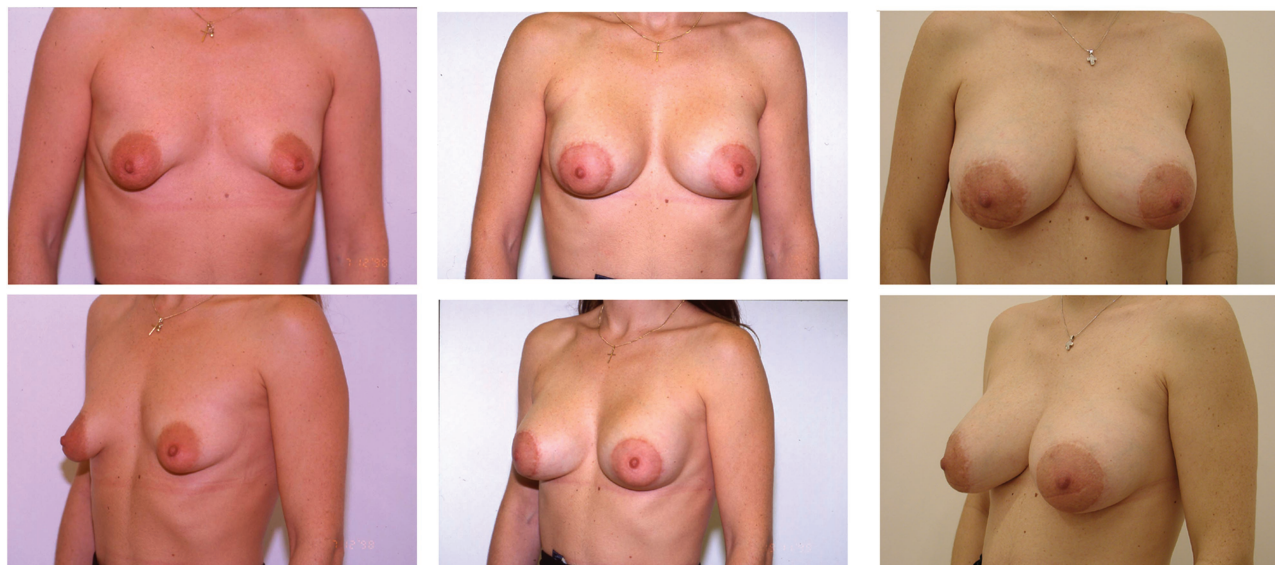


FIG. 4. Thirty-year-old patient (case 3) with bilateral type II tuberous breast deformity. The main features of the deformity are underdevelopment of the inferior pole of the breast with slightly increased areolar diameter. A periareolar donut-type excision was followed by readjustment of the breast parenchyma and insertion of 225-cc silicone breast implants. The patient subsequently got pregnant 3 years after the original operation. (Above) Frontal views and (below) left oblique views, preoperatively, 1 year postoperatively, and 3 years postoperatively (the patient was 20 weeks pregnant).

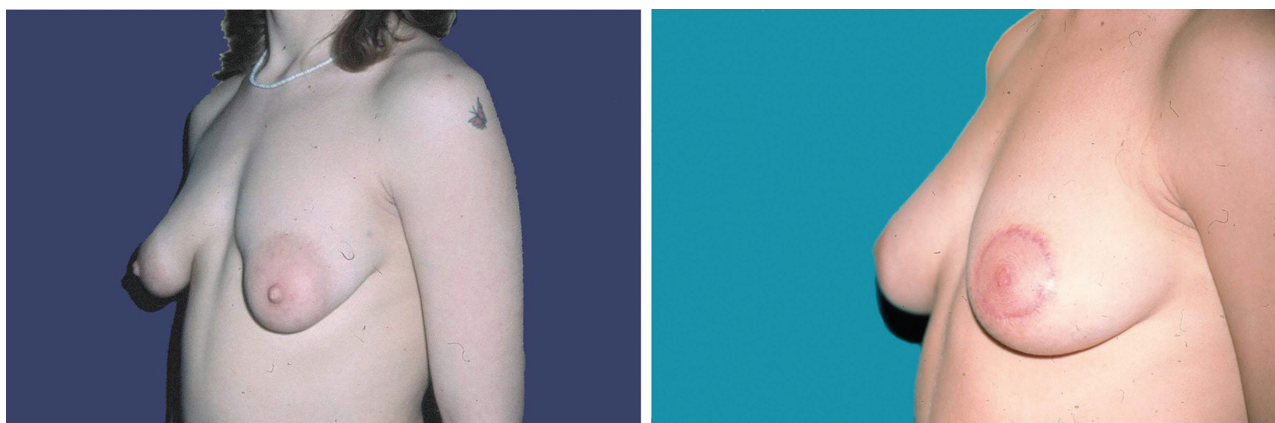


FIG. 5. Twenty-two-year-old patient (case 5) with bilateral type II tuberous breast deformity with underdevelopment of the inferior pole of both breasts. A periareolar donut-type excision was combined with our technique to readjust the breast parenchyma, without the need to use silicone breast implants. Left oblique views, preoperatively and 6 months postoperatively.

tioned (Table II). The first two parameters were scored by the surgical team, and the third one was scored by the patient, all at 3 to 6 months from the time of the procedure.

The results are presented in Table I. In general, correction of the deformity was excellent and symmetry was very good, apart from cases 6 and 11, with asymmetrical deformity (types III and II and types III and I, respectively), in which good symmetry could not be achieved (Figs. 6 and 8). Nonetheless, patient satisfaction was very high, even in these two cases.

There were no complications in this series of 11 patients.

#### DISCUSSION

The tuberous breast deformity was first described in 1976 by Rees and Aston.<sup>3</sup> Since then, several authors have attempted to describe, classify, and correct the problem by utilizing different methods with varying results.<sup>1,2,4-14,19,21-26</sup> The large number of articles published on the subject demonstrates the psychological morbidity that the deformity can cause, as well as the difficulty in developing a satisfactory surgical solution to the problem.

We have been dealing with this problem for several years, and the initial unsatisfactory re-

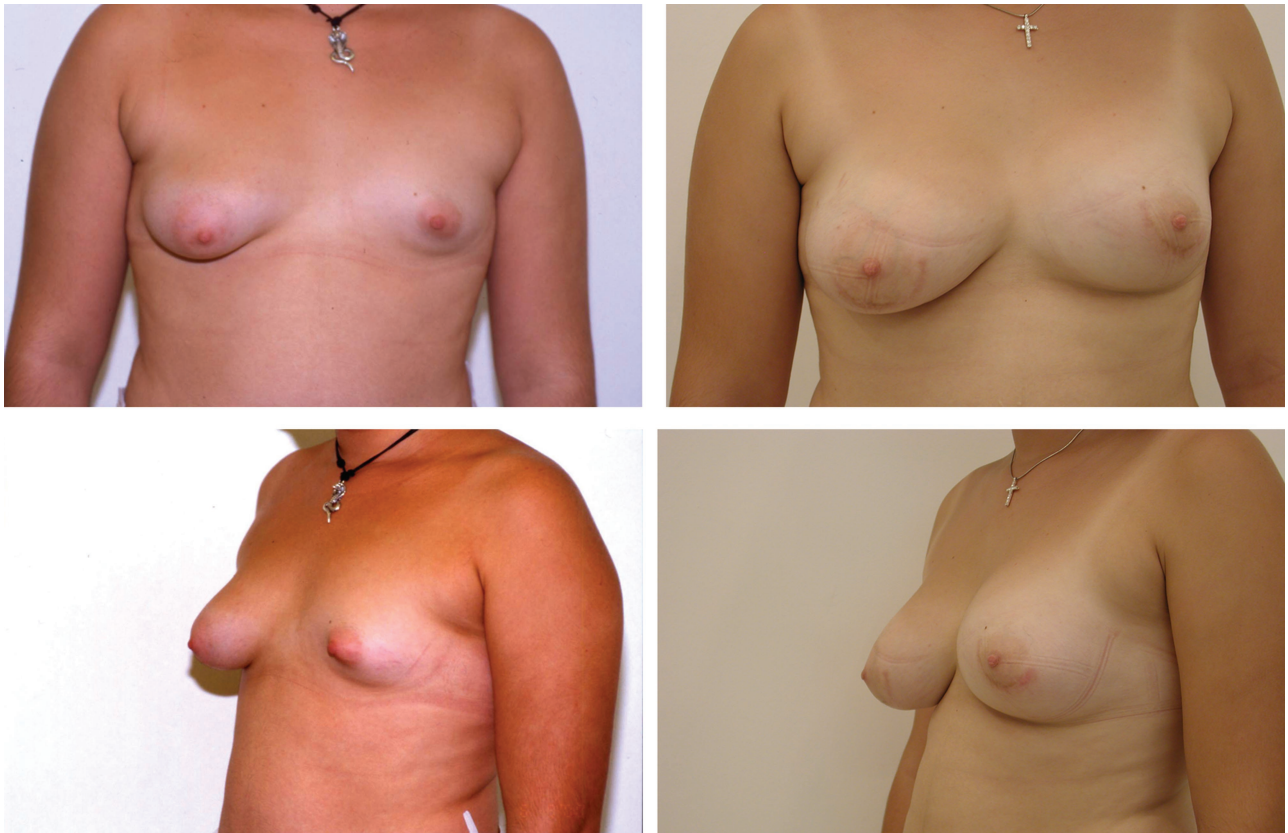


FIG. 6. Seventeen-year-old patient (case 6) with bilateral asymmetrical tuberous breast deformity. The right breast is characterized by underdevelopment of the inferior pole (type II), while on the left side there is severe hypoplasia of the whole breast (type III). Both breasts were treated with semicircular periareolar incision, readjustment of the breast parenchyma, and subglandular placement of silicone breast implants (right breast, 200 cc; left breast, 300 cc). Frontal and left oblique views, preoperatively and 8 months postoperatively.

sults achieved when conventional methods were used led us back to the basics to find the answers we needed. The study of the anatomy and embryology of the breast enabled us to understand the nature of the deformity and to formulate a surgical approach capable of restoring normal breast aesthetics.

Other authors have also referred to the embryology of breast development, but the theories put forward are far from satisfactory. Glaesmer suggested a phylogenetic relapse (1930),<sup>6</sup> and Pers (1968) postulated that there is failure of tissue differentiation in a limited zone of the fetal thorax.<sup>6</sup> Pers' theory might be suitable to explain deformities in the line of amastia and Poland's syndrome, but as far as the tuberous breast deformity is concerned, we believe that things are much simpler than what both of these theories suggest and that the only aberration is a thickening of the superficial fascia,<sup>5</sup> as it has already been explained in detail.

Our own understanding of the development of the deformity is as follows: during the tenth

to fourteenth week of fetal development, the developing breast, which is ectodermal in origin, starts pushing inward into the underlying mesenchyme. As a result, the breast is enclosed within a fascial envelope, with the only point not covered by this fascia being the point of entry, which subsequently develops to become the nipple-areola complex.

The absence of the superficial layer of the superficial fascia underneath the areola<sup>15,17</sup> coupled with the "constricting ring"<sup>2</sup> formed by the thickening of the superficial fascia,<sup>5</sup> especially in the lower pole of the breast, inhibits the expansion of the developing breast and leads to a herniation of the breast parenchyma toward the nipple-areola complex. As already mentioned, the severity of the deformity ranges from mild hypoplasia of the inferior medial quadrant of the breast to major hypoplasia of all four quadrants with varying degrees of herniation and areola enlargement.<sup>5,6,14,20</sup>

Many scientists have addressed the issue of this constricting ring,<sup>19,27,28</sup> but no one has ac-



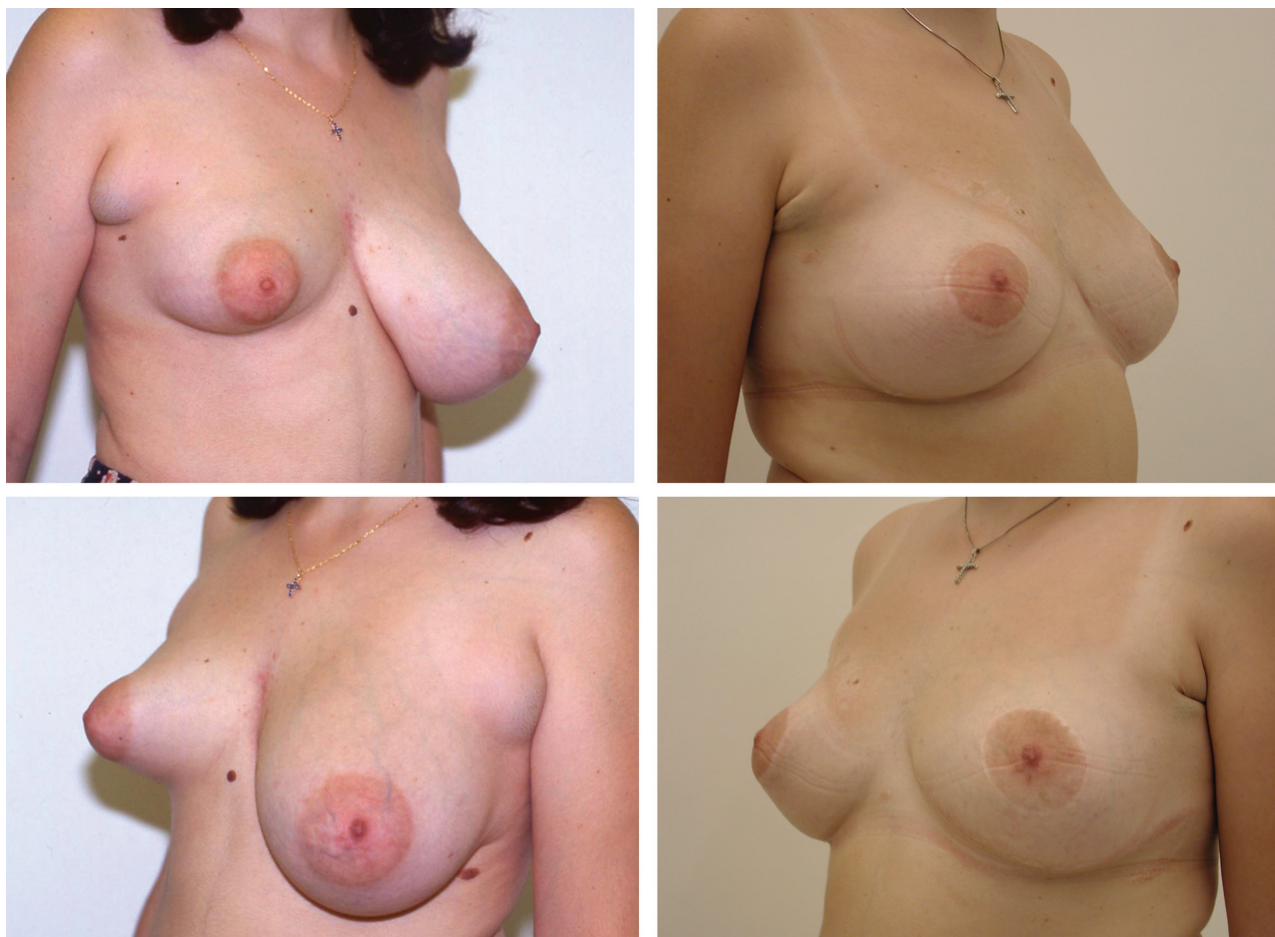


FIG. 7. Twenty-three-year-old patient (case 8) with type II right tuberous breast deformity with hypoplasia of the inferior pole, herniation of the breast parenchyma toward the nipple-areola complex, and moderately increased areolar diameter. The left breast is slightly large with Regnault's class A ptosis.<sup>31</sup> The right breast was treated with periareolar donut-type excision and readjustment of the breast parenchyma without the use of an implant; the left breast was treated with inferior pedicle-type breast reduction coupled with excision of the axillary tail of Spence. Right and left oblique views, preoperatively and 1 year postoperatively.

tually looked into its nature. Anatomical and histological studies of the tissues involved would be an interesting addition to confirm these anecdotal reports.

Most authors acknowledge that merely placing an implant behind the deformed breast accentuates the deformity instead of correcting it.<sup>3,5,10,13,29</sup> Some authors advocate that there is skin deficiency in the inferior part of the breast,<sup>2,12,14,22</sup> with the inframammary fold being situated much higher than normal, but if one carefully examines the affected breast, the skin in the inferior part of the breast is lax, and the constriction lies deep within the subcutaneous tissue.<sup>2,19</sup>

Failure to address this problem is the main reason why the results yielded by most methods are far from satisfactory. There are, however, some authors who have focused on this point and

have tried to rearrange the breast parenchyma to mold a more natural-looking breast.

Rees and Aston<sup>3</sup> were the first to discuss radial incisions on the back of the breast to expand its base, but their technique did not actually transect the constricting ring. Dinner and Dowden<sup>12</sup> realized that there was something constricting the breast in its inferior pole, but they thought that it was the skin that was responsible for this constriction. They therefore used a full-thickness incision through skin, subcutaneous tissue, and breast to release it, followed by transposition of a skin and subcutaneous tissue flap.<sup>12</sup> Other authors have tried to rearrange the inferior pole of the breast, transecting the breast parenchyma horizontally and then unfolding the flap inward or outward,<sup>5,19,30</sup> but the results have not always been aesthetically satisfactory.

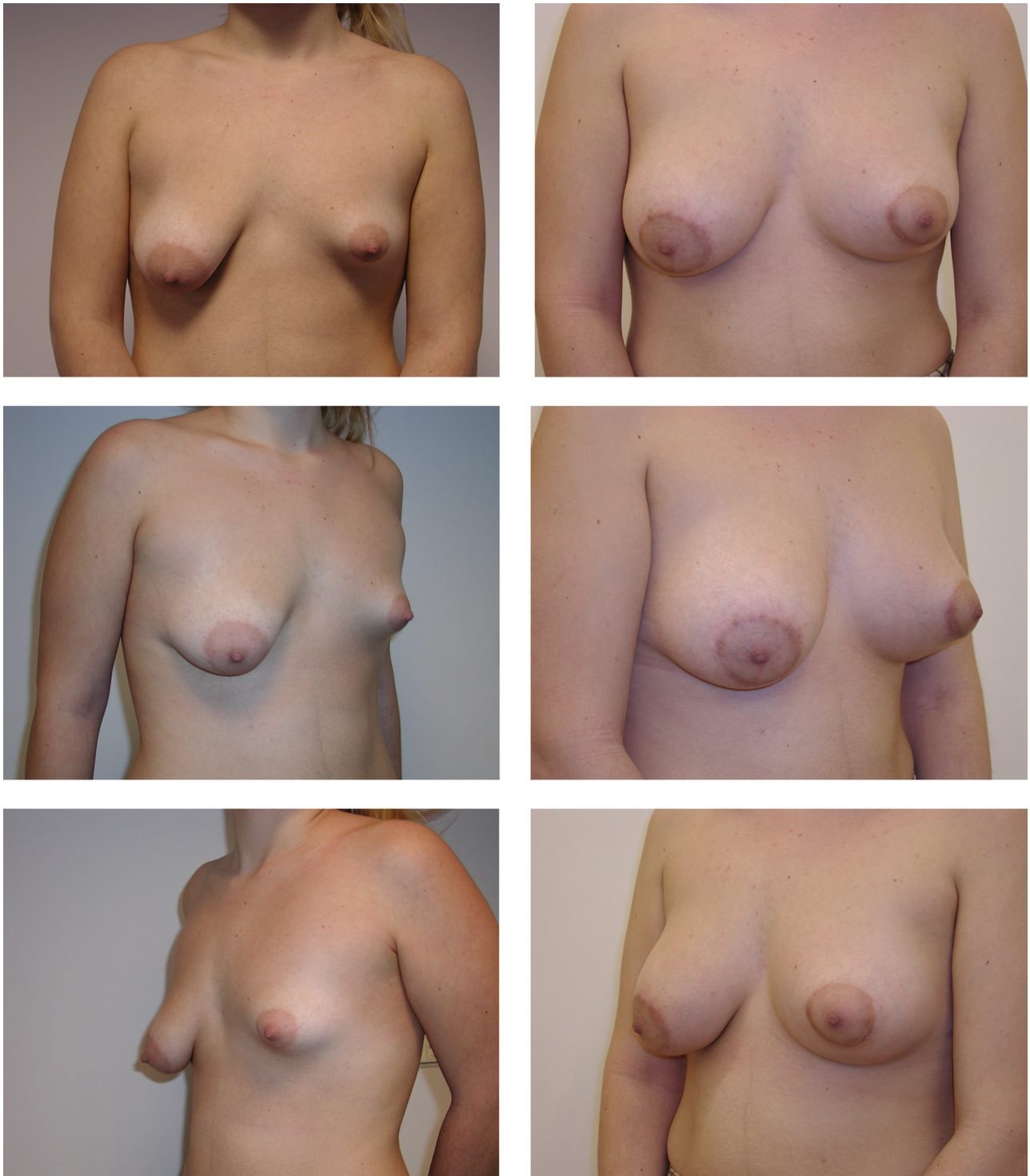


FIG. 8. Twenty-one-year-old patient (case 11) with asymmetrical tuberous breast deformity. The right breast is characterized by underdevelopment of the inferior medial quadrant (type I), while on the left side there is severe constriction in both horizontal and vertical axes (type III). The right breast was treated with periareolar donut-type excision and readjustment of the breast parenchyma without the use of an implant. The left breast was treated with a semicircular periareolar incision, readjustment of the breast parenchyma, and subglandular placement of a 225-cc silicone breast implant. Frontal, right, and left oblique views, preoperatively and 5 months postoperatively.



TABLE II  
Outcomes Scales

Scale	Surgical Team		Patient Satisfaction
	Correction of Deformity	Symmetry	
1	Inadequate	Very asymmetrical	Not satisfied
2	Good	Slight asymmetry	Satisfied
3	Excellent	Good symmetry	Very satisfied

Of note is the technique developed by Ribeiro et al.,<sup>19,27,31</sup> which in principle is very similar to ours. Ribeiro recognizes the existence of the constricting ring that needs to be transected to allow the breast to reshape. Ribeiro transects the ring in a horizontal axis and then develops a flap from the inferior portion of the breast to enhance the projection of the hypoplastic breast, thereby doing away with implants, as his patients are not particularly concerned with large breast volumes.<sup>32</sup>

Our approach is slightly different. The constricting ring is transected at the 6 o'clock semiaxis of the breast, thus creating two pillars in the inferior part of the breast. The pillars are then either just loosely reapproximated using absorbable sutures or folded over each other in the fashion of a "double-breasted" jacket to add volume in the inferior portion of the breast—with the optional addition of a breast implant underneath it to correct any volume deficiency.

We believe that our technique is simple, is technically easy, and it yields consistently good results. The scars are confined to the periareolar margin and are, most of the time, virtually invisible. There is the additional advantage of not disturbing the lactiferous ducts, thus allowing normal breast function (provided adequate breast parenchyma was present before the procedure).

*Apostolos D. Mandrekas, M.D.*

*11 D. Vassiliou Street*

*N. Psychiko*

*Athens 15451, Greece*

*amandrekas@artion-plasticsurgery.com*

## REFERENCES

1. Toranto, I. R. Two-stage correction of tuberous breast. *Plast. Reconstr. Surg.* 67: 642, 1981.
2. Atiyeh, B. S., Hashim, H. A., El-Douaihy, Y., and Kayle, D. I. Perinipple round-block technique for correction of tuberous/tubular breast deformity. *Aesthetic Plast. Surg.* 22: 284, 1998.
3. Rees, T. D., and Aston, S. J. The tuberous breast. *Clin. Plast. Surg.* 3: 339, 1976.
4. Williams, J. E. Two-stage correction of tuberous breast (Discussion). *Plast. Reconstr. Surg.* 67: 647, 1981.
5. Grolleau, J.-L., Lanfrey, E., Lavigne, B., Chavoin, J.-P., and Costagliola, M. Breast base anomalies: Treatment strategy for tuberous breasts, minor deformities, and asymmetry. *Plast. Reconstr. Surg.* 104: 2040, 1999.
6. von Heimburg, D., Exner, K., Kruft, S., and Lemperle, G. The tuberous breast deformity: Classification and treatment. *Br. J. Plast. Surg.* 49: 339, 1996.
7. Gruber, R. P., and Jines, H. W., Jr. The "donut" mastopexy: Indications and complications. *Plast. Reconstr. Surg.* 65: 34, 1980.
8. Panetti, P., Del Gaudio, G.-A., Marchetti, L., Accorsi, D., and Del Gaudio, A. The tuberous breast syndrome. *Aesthetic Plast. Surg.* 24: 445, 2000.
9. Gasperoni, C., Salgarello, M., and Gargani, G. Tubular breast deformity: A new surgical approach. *Eur. J. Plast. Surg.* 9: 141, 1987.
10. Teimourian, B., and Adham, M. N. Surgical correction of the tuberous breast. *Ann. Plast. Surg.* 10: 190, 1983.
11. Bruck, H. G. Hypoplasia of the lower medial quadrant of the breast. *Aesthetic Plast. Surg.* 16: 283, 1992.
12. Dinner, M. I., and Dowden, R. V. The tubular/tuberous breast syndrome. *Ann. Plast. Surg.* 19: 414, 1987.
13. Scheepers, J. H., and Quaba, A. A. Tissue expansion in the treatment of tubular breast deformity. *Br. J. Plast. Surg.* 45: 529, 1992.
14. Meara, J. G., Kolker, A., Bartlett, G., Theile, R., Mutimer, K., and Holmes, A. D. Tuberous breast deformity: Principles and practice. *Ann. Plast. Surg.* 45: 607, 2000.
15. Hughes, L. E., Mansel, R. E., and Webster, D. J. T. Breast anatomy and physiology. In L. E. Hughes, R. E. Mansel, and D. J. T. Webster (Eds.), *Benign Disorders and Diseases of the Breast: Concepts and Clinical Management*. London: Bailliere Tindal, 1989. Pp. 5–14.
16. Osborne, M. P. Breast development and anatomy. In J. R. Harris, S. Hellman, I. C. Henderson, and D. W. Kinne (Eds.), *Breast Diseases*, 2nd Ed. Philadelphia: J. Lippincott Co., 1991. Pp. 1–13.
17. Moore, K. L. The integumentary system. In K. L. Moore, *The Developing Human: Clinically Oriented Embryology*, 4th Ed. Philadelphia: Saunders, 1988. Pp. 426–428.
18. Bostwick, J., III. Anatomy and physiology. In J. Bostwick, III (Ed.), *Plastic and Reconstructive Breast Surgery*, 2nd Ed. St. Louis, Mo.: Quality Medical Publishing, 2000. Pp. 89–93.
19. Ribeiro, L., Canzi, W., Buss, A., and Accorsi, A., Jr. Tuberous breast: A new approach. *Plast. Reconstr. Surg.* 101: 42, 1998.
20. von Heimburg, D. Refined version of the tuberous breast classification. *Plast. Reconstr. Surg.* 105: 2269, 2000.
21. Argenta, L. C., VanderKolk, C., Friedman, R. J., and Marks, M. Refinements in reconstruction of congenital breast deformities. *Plast. Reconstr. Surg.* 76: 73, 1985.
22. Elliott, M. P. A musculocutaneous transposition flap mammaplasty for correction of the tuberous breast. *Ann. Plast. Surg.* 20: 153, 1988.
23. Wilkinson, T. S. Re: Elliott: Mammaplasty for the tuberous breast. *Ann. Plast. Surg.* 21: 294, 1988.
24. Marchioni, E. E. Surgical treatment of tuberous breasts with bilateral mega-areola with a periareolar scar technique. *Ann. Plast. Surg.* 30: 363, 1993.
25. Kneafsey, B., Crawford, D. S., Khoo, C. T. K., and Saad,

- M. N. Correction of developmental breast abnormalities with a permanent expander/implant. *Br. J. Plast. Surg.* 49: 302, 1996.
26. Muti, E. Personal approach to surgical correction of the extremely hypoplastic tuberous breast. *Aesthetic Plast. Surg.* 20: 385, 1996.
27. Ribeiro, L., Accorsi, A., Jr., Buss, A., and Marcal-Pessoa, M. C. Short scar correction of the tuberous breast. *Clin. Plast. Surg.* 29: 423, 2002.
28. Gasperoni, C. Personal communication. Athens, Greece, 1998.
29. de la Fuente, A., and Martin del Yerro, J. L. Periareolar mastopexy with mammary implants. *Aesthetic Plast. Surg.* 16: 337, 1992.
30. Puckett, C. L., and Concannon, M. J. Augmenting the narrow-based breast: The unfurling technique to prevent the double-bubble deformity. *Aesthetic Plast. Surg.* 14: 15, 1990.
31. Regnault, P. Breast ptosis: Definition and treatment. *Clin. Plast. Surg.* 3: 193, 1973.
32. Ribeiro, L., Accorsi, A., Jr., Buss, A., and Marcal-Pessoa, M. Creation and evolution of 30 years of the inferior pedicle in reduction mammoplasties. *Plast. Reconstr. Surg.* 110: 960, 2002.