

Aesthetic Reconstruction of the Tuberous Breast Deformity: A 10-Year Experience

Apostolos D. Mandrekas, MD, PhD; and George J. Zambacos, MD

Aesthetic Surgery Journal
30(5) 680–692
© 2010 The American Society for
Aesthetic Plastic Surgery, Inc.
Reprints and permission:
[http://www.sagepub.com/
journalsPermissions.nav](http://www.sagepub.com/journalsPermissions.nav)
DOI: 10.1177/1090820X10383397
www.aestheticsurgeryjournal.com


Abstract

Background: Tuberous breast deformity is a developmental aberration of the breast whereby a constricting ring on the base of the breast prevents its expansion on the horizontal and/or the vertical axis. This leads to the well-known “tuberous” appearance of the breast, causing a herniation of the breast tissue toward the nipple-areola complex due to the increased pressure. Several techniques have been proposed to correct this deformity, but the aesthetic results have generally been poor.

Objective: The authors present their theory on the etiology of the deformity, which has been further substantiated by their histological series of patient findings over the course of 10 years. They also present their technique and experience in treating 22 patients (41 breasts) over the past 10 years.

Methods: Twenty-two women (41 breasts) with tuberous breast deformity were treated in the authors’ private clinic over the past 10 years. Treatment protocol included a periareolar incision followed by a reconstruction of the breast tissue through transection of the constricting ring and formation of two breast pillars, which were folded toward one another to provide the missing volume on the inferior part of the breast. A silicone breast implant could also be placed subglandularly or submuscularly for additional volume. The oversized nipple areola complex was addressed via a donut-type periareolar excision.

Results: Bruising and swelling commonly resulted from application of this technique, but this is a predictable postoperative symptom. In terms of complications, there was one case of hematoma on the right breast of a bilateral reconstruction, which had to be evacuated. No patients had skin necrosis or loss of nipple sensation. The same patient who developed a hematoma developed a Baker III case of capsular contracture in the same breast. One patient developed asymmetry but refused revision. All scars were confined to the periareolar margin and were virtually invisible.

Conclusions: The authors propose a technique that is simple and yields consistently good results for the treatment of tuberous breast deformity. This technique has the added advantage of not disturbing the lactiferous ducts, thus preserving normal breast function. Patients who have been treated by the authors with this method over the past 10 years have experienced good postoperative results with few complications, and it provides a strong alternative to the existing but varied techniques for addressing the deformity.

Keywords

breast surgery, tuberous breast, congenital breast, breast asymmetry, breast implants

Accepted for publication November 20, 2009.

The tuberous breast deformity is a rare condition that affects teenage women either unilaterally or bilaterally.^{1,2} Its exact incidence has not been properly investigated and remains undetermined.^{1–3} Nonetheless, this deformity produces significant psychological morbidity and presents a reconstructive challenge for the plastic surgeon.

Since its first description in 1976 by Rees and Aston,⁴ many names (tuberous breasts,^{4,5} tubular breasts,^{4–6} Snoopy breasts,^{5–9} herniated areolar complex,^{5,6,9,10} domed nipple,^{9,10} nipple breast,^{9,11} constricted breast,⁶ lower pole hypoplasia,^{5,6} and narrow-based breast^{5,6}) have been applied to describe the same deformity, which is further evidence of the confusion that exists among plastic surgeons regarding this condition.¹² No matter the name, the

symptomatic anomaly is characterized by a deficiency in the vertical and/or horizontal dimensions of the breast, frequent underdevelopment of the breast, and often a herniation of breast tissue into the areola accompanied by expansion of the areola (Figure 1).^{1,2,4,6,8–10,13–15}

Drs. Mandrekas and Zambacos are in private practice in Athens, Greece.

Corresponding Author:

Dr. Apostolos Mandrekas, 11 D. Vassiliou Street, N. Psychiko, Athens 15451, Greece.
E-mail: amandrekas@artion-plasticsurgery.com

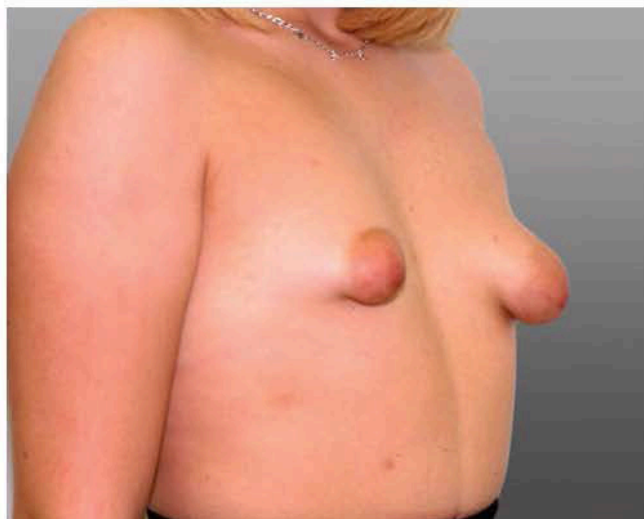

Figure 1. A typical case of bilateral tuberous breast deformity, with deficiency in both the vertical and horizontal dimensions of the breast, underdevelopment of the breast, herniation of breast tissue toward the areola, and expansion of the areola on the left side.

ANATOMY AND EMBRYOLOGY

A critical step in understanding the nature of the deformity is a review of the breast's embryology. The breast originates from the mammary ridge, which develops in utero from the ectoderm during the fifth week.^{16,17} Shortly after its formation (in the seventh to eighth weeks), most parts of this ridge disappear, except for a small portion in the thoracic region, which persists and penetrates the underlying mesenchyme around 10 to 14 weeks.¹⁷ Further differentiation and development of the breast occurs during the intrauterine life and is completed by the time of birth, after which essentially no further development occurs until puberty.¹⁶

During puberty, the mammary tissue beneath the areola grows with enlargement of the areola, until the age of 15 to 16, when the breast assumes its familiar shape.¹⁶⁻¹⁸ As a result of the ectodermal origin of the breast and its invagination into the underlying mesenchyme, the breast tissue is contained within a fascial envelope, the superficial fascia.^{16,17,19} This superficial fascia is continuous with the superficial abdominal fascia of Camper and consists of two layers: the superficial layer (which is the outer layer covering the breast parenchyma) and the deep layer (which forms the posterior boundary of the breast parenchyma and lies on the deep fascia of the pectoralis major and serratus anterior muscles).^{16,17,19} The deep layer of the superficial fascia is penetrated by fibrous attachments (suspensory ligaments of Cooper), joining the two layers of the superficial fascia and extending to the dermis of the overlying skin and the deep pectoral fascia.^{16,17,19} Of note is that the superficial layer of this fascia is absent in the area underneath the areola, as can easily be demonstrated by the invagination of the mammary bud in the mesenchyme.¹⁸

Clinical experience has shown us²⁰ and other authors^{2,21} that in cases of tuberous breasts, there is a constricting fibrous ring at the level of the periphery of the nipple-

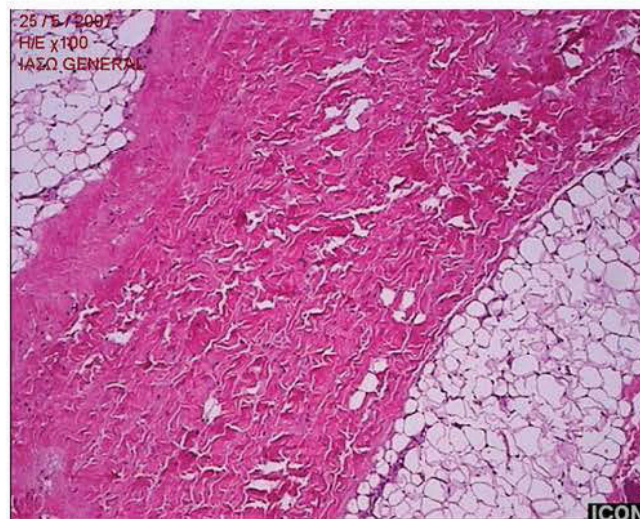


Figure 2. Hematoxylin and eosin (H&E) staining of tissue taken from the clinically palpable fibrous ring (100 \times). Note the dense fibrosis with stromal thickening and large concentrations of collagen and elastic fibers arranged longitudinally.

areolar complex that inhibits the normal development of the breast. This constricting ring of fibrous tissue is denser at the lower part of the breast and does not allow the developing breast parenchyma to expand during puberty. Histology confirmed the existence of such dense fibrous tissue in the area of this "constricting ring." Specimens from two of our patients have been examined, and they showed large concentrations of collagen and elastic fibers, arranged longitudinally (Figure 2). We believe this ring represents a thickening of the superficial fascia, as described earlier. Perhaps the two layers of this fascia join at a higher level than usual, or the suspensory ligaments are thicker and more dense.⁵

Whatever the reason for this constricting ring, the developing breast cannot expand inferiorly,⁵ and because there is no superficial layer of the superficial fascia under the areola (as noted above), the breast parenchyma herniates toward the nipple-areolar complex. The severity of the deformity depends on the severity of the malformation of the superficial fascia and ranges from slight underdevelopment of the inferior medial quadrant of the breast with near-normal breast volume to major hypoplasia of all four quadrants with various degrees of herniation of the breast parenchyma toward the areola, as already described in several classifications submitted over the years.^{5,6,15,22} We have adopted the classification of Grolleau et al,⁵ according to which deficiency of the lower medial quadrant is type I (Figure 3A), deficiency of both lower quadrants is type II (Figure 3B), and deficiency of all four quadrants is type III (Figure 3C,D).

METHODS

Twenty-two patients were treated with our technique in the past 10 years, 19 with bilateral and three with unilateral deformity (for a total of 41 breasts). Each procedure began with the preoperative marking of the new inframammary fold

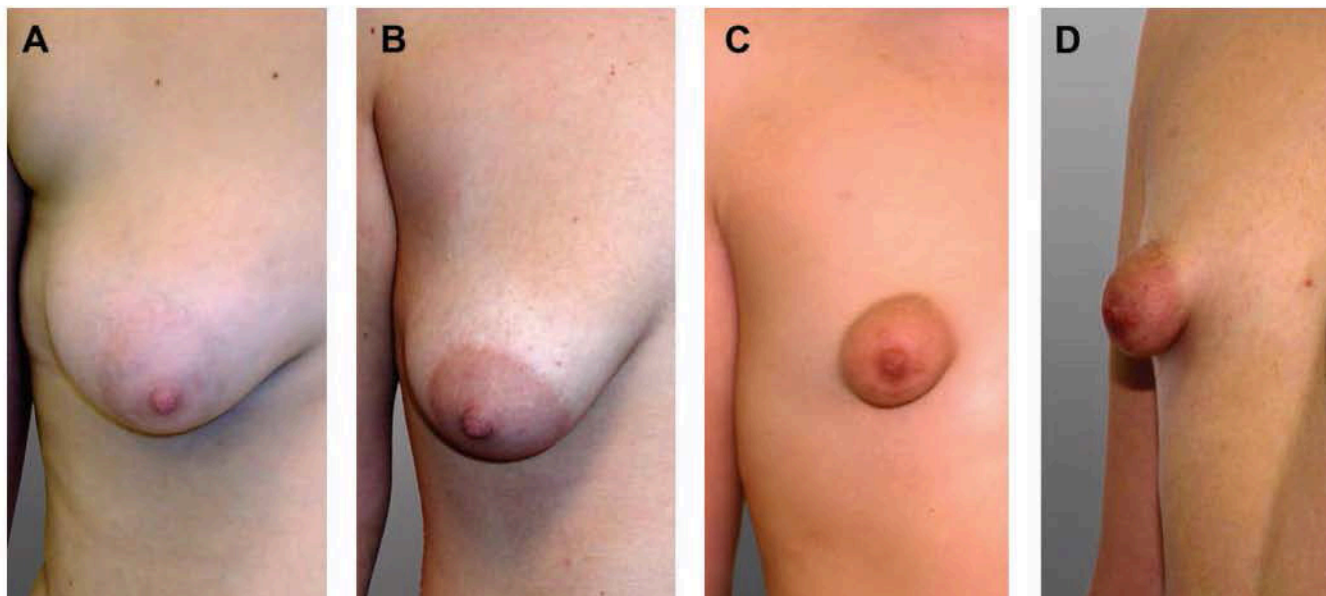


Figure 3. These breasts illustrate the classification of tuberous breast deformity proposed by Grolleau et al⁵ and adopted by the authors. (A) Type I: deficiency of the lower medial quadrant. (B) Type II: deficiency of both lower quadrants. (C, D) Type III: deficiency of all four quadrants.

in the standing and the supine position, with the projection of the contralateral breast as a guide in unilateral cases and the sixth rib as a landmark in bilateral cases.⁸ The breast was infiltrated with a lidocaine/epinephrine solution (20 mL 0.5% lidocaine solution with 1:400,000 epinephrine), as we do with all breast surgery cases.²³

A periareolar donut-type skin deepithelialization was performed where appropriate to reduce the areola to the desired size, usually 4 to 4.5 cm in diameter (Figure 4A). The skin of the inferior half of the breast was undermined down to the pectoralis fascia with sharp dissection (Figure 4B and Figure 5). Once the lower border of the breast parenchyma was reached, the dissection continued further, toward the new inframammary fold (Figure 6A). We then proceeded upward with blunt and sharp dissection behind the breast, along the natural plane between the deep layer of the superficial fascia and the deep fascia (Figure 6B). The breast parenchyma was dissected off the deep pectoral fascia, leaving only the superior part of the breast attached. The dissection was also extended laterally and medially, and the breast parenchyma was exteriorized through the periareolar opening (Figure 7).

The exteriorized inferior half of the breast was transected with a vertical incision along the middle. By transecting the lower pole of the breast, we divided this constricting ring, freeing up the breast and creating two pillars (Figure 8A). The tuberous breast is long with a narrow base, and by transecting the lower pole, we were able to spread the breast tissue, thus achieving a breast shape that was flatter and wider, usually at the expense of projection. (This is possible because breast tissue is not rigid and allows some molding.) To avoid leaving a gap at the six o'clock margin, where the transection takes place, we tried bring the pillars loosely together with sutures (Figure 8B). We were not repairing the transected breast and certainly not reconstituting the

constricting ring. If the pillars were short, they were loosely approximated with absorbable sutures (4-0 Vicryl; Ethicon, Inc., Somerville, New Jersey). If the two pillars were long (Figure 9), then the proximal parts were again approximated with absorbable sutures, and the distal parts were either allowed to redrape freely or were folded over each other like a "double-breasted" jacket to manufacture added volume in the inferior portion of the breast, exactly where it was lacking initially, which gave a more natural shape.

On rare occasions, we secured the lower part of the pillars at the new inframammary fold with bolster-type sutures. This was the case when the pillars were short and therefore unable to reach the new inframammary fold freely. If necessary, a silicone breast implant was placed to increase the volume of the breast. The implant could be placed in a purely subglandular or a dual-plane position (upper part submuscular, lower part subcutaneous/subglandular), depending on the individual patient's configuration. Care was taken to ensure that the pillars covered the implant in its entirety. The decision to place a breast implant was usually made at the preoperative consultation, where surgeon and patient discussed whether additional volume would be required. Round, textured silicone gel implants were usually selected.

The periareolar incision was then sutured in layers with deep subcutaneous and intradermal sutures of long-lasting dissolvable material (4-0 PDS or Monocryl; Ethicon, Inc.). So far, with a maximum follow-up of 10 years, we have not had any issues with stretching of the periareolar scar. The resulting breast has a normal-sized areola, a natural shape, a volume matching the contralateral breast, and no evidence of the "double-bubble" deformity. Clinical results are pictured in Figures 11 to 14. An additional patient is pictured in a series of online photos (Figure 15; www.aestheticsurgeryjournal.com).

RESULTS

With this technique, bruising and swelling were the most common complications (Table 1). This is considerable, it is almost always to be expected, and the expectation should be relayed to patients beforehand, so they are not alarmed when they first see their breasts.

Hematoma formation was probably the next most common complication to be expected; to combat it, meticulous hemostasis was performed. In our series of 22 patients (41 breasts) with a maximum follow-up of 10 years, we had one case of hematoma on the right breast of a bilateral reconstruction, which had to be evacuated. Nonetheless, we do not place drains routinely.

Another complication that should be avoided by careful technique is skin necrosis in the lower part of the breast. The technique requires subcutaneous dissection in the lower half of the breast and care should be taken not to make the flaps too thin or damage the skin by careless application of the electrocautery.

Nipple-areolar sensation could be affected if the subglandular dissection is extended superolaterally, so care should be taken to avoid damaging the fourth and fifth intercostal nerves. Capsular contracture has been recognized in one case from our series (Baker III, in the patient who developed the hematoma, and on the side of the hematoma; Figure 14 J,K), but the risk should be equal to that of breast augmentation patients if an implant has been placed. Asymmetry was present in one of our cases (Figure 12), but the patient refused to undergo further surgery.

Our overall revision/reoperation rate with a maximum follow-up of 10 years and a minimum follow-up of 18 months was 0%. This does not mean that all cases were perfect but rather that our patients were satisfied with their result even if there were minor problems.

DISCUSSION

Since the original report by Rees and Aston in 1976,⁴ multiple authors have attempted to describe, classify, and correct tuberous breast deformity through various methods with varying results,^{1,2,5-15,24-29} demonstrating the difficulty in developing a satisfactory surgical solution to the problem. We have been treating patients with this problem for more than 10 years, but it was not until we examined the anatomy and embryology of the breast that we were able to understand the nature of the deformity and formulate a surgical approach capable of restoring normal breast aesthetics.

Other authors have also referred to the embryology of breast development, but the theories put forth have been unsatisfactory. Glaesmer suggested a phylogenetic relapse (1930), and Pers (1968) postulated that there was failure of tissue differentiation in a limited zone of the fetal thorax.⁶ We believe that the deformity develops as follows: during the 10th to 14th weeks, the developing breast, which is ectodermal in origin, invaginates into the underlying mesenchyme. As a result, the breast is enclosed within a fascial envelope from the superficial fascia, with the only part not covered by this fascia being the point of

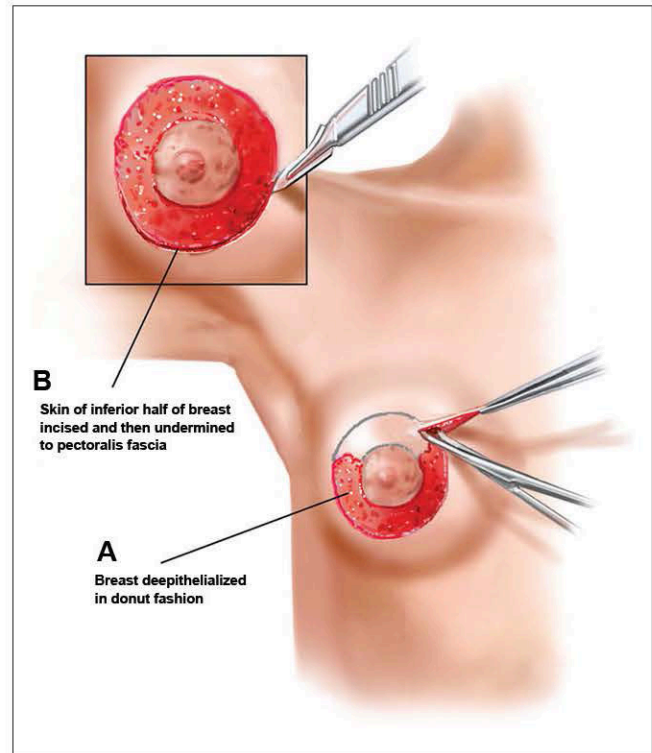


Figure 4. (A) A periareolar donut-type skin deepithelialization is performed where appropriate to reduce the areola to the desired size. (B) The skin of the inferior half of the breast is incised and then undermined down to the pectoralis fascia with sharp dissection.

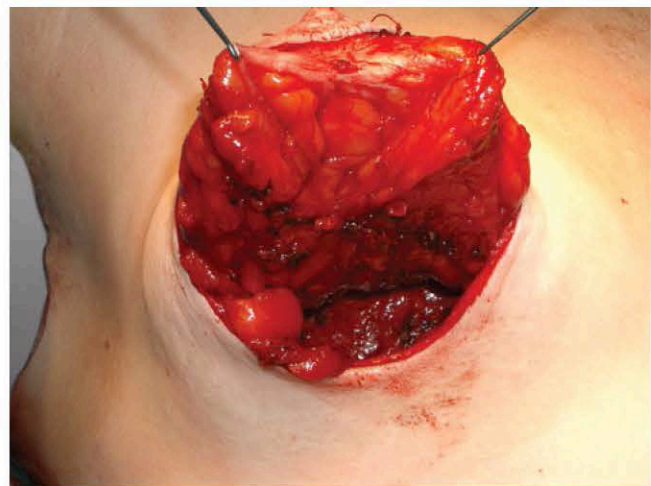


Figure 5. The inferior skin incision and undermining is shown intraoperatively. The undermining continues down to the pectoralis fascia with sharp dissection.

entry, which subsequently develops into the nipple-areolar complex. The absence of the superficial layer of this fascia underneath the areola,^{16,18} coupled with the “constricting ring”² formed by the thickening of the superficial fascia⁶ (especially in the lower pole of the breast), inhibits the expansion of the developing breast and leads to a herniation of the breast parenchyma toward the nipple areola

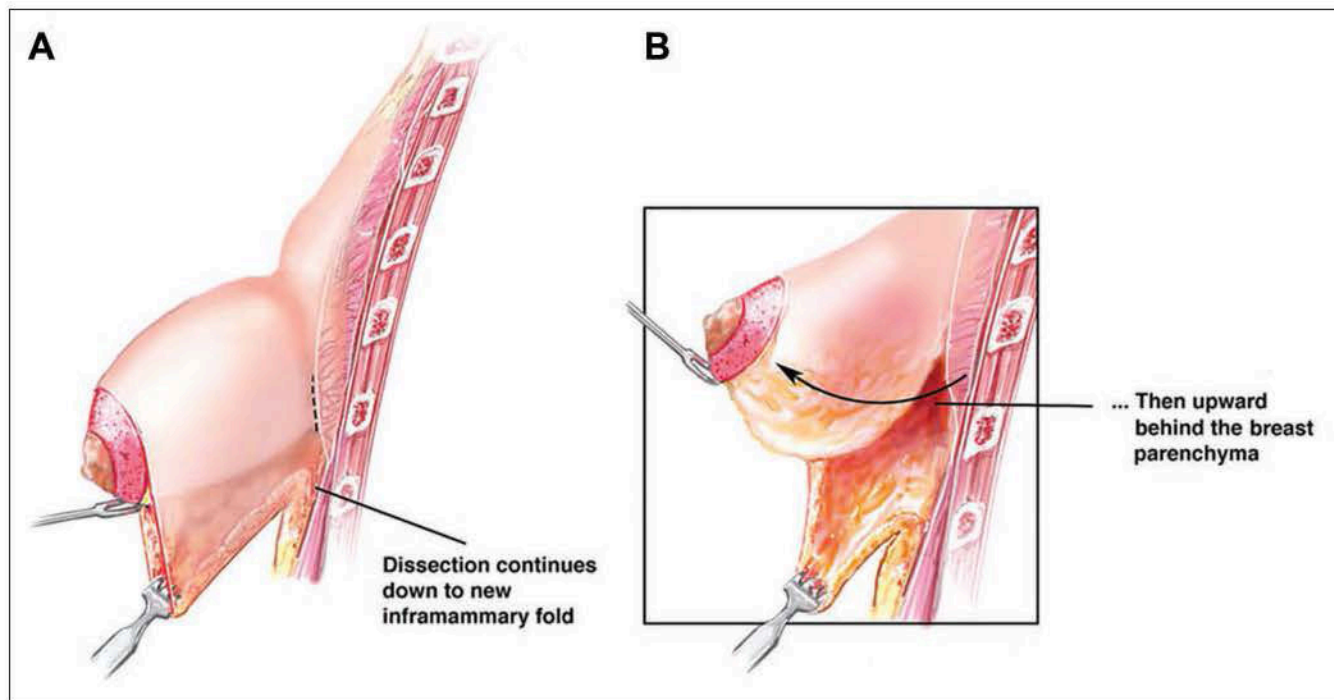


Figure 6. (A) Once the lower border of the breast parenchyma is reached, dissection continues further toward the new inframammary fold. (B) Blunt and sharp dissection then proceeds upward behind the breast, along the natural plane between the deep layer of the superficial fascia and the deep fascia.

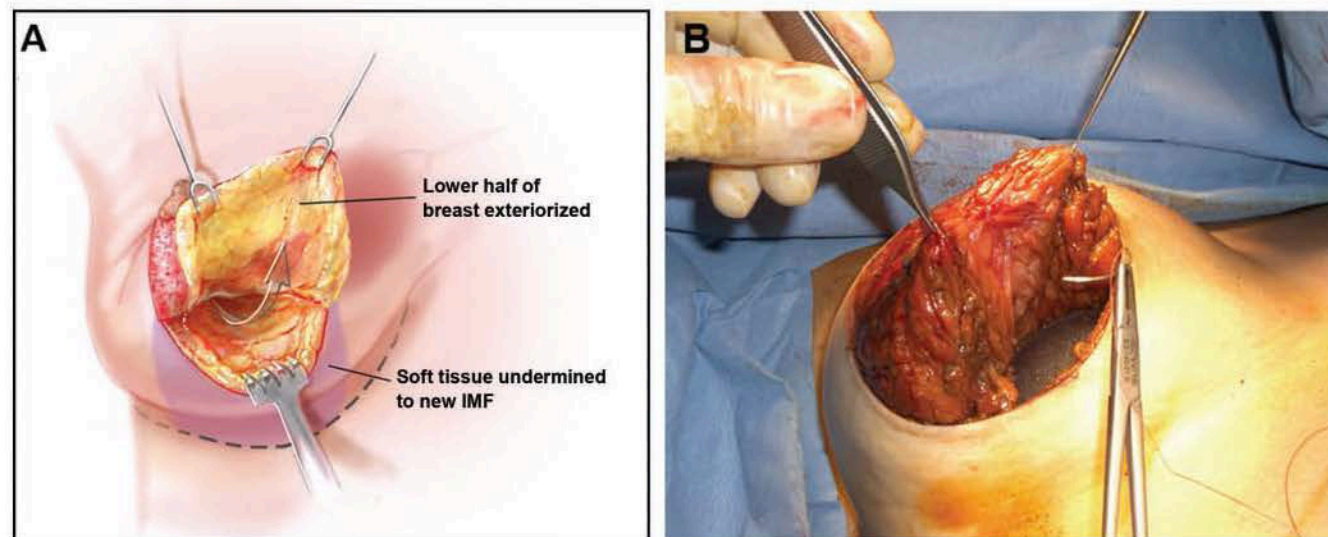


Figure 7. (A, B) The breast parenchyma is dissected off the deep pectoral fascia, leaving only the superior part of the breast attached. The dissection also extends laterally and medially, and the breast parenchyma is exteriorized through the periareolar opening.

complex. As already mentioned, the severity of the deformity ranges from mild hypoplasia of the inferior medial quadrant of the breast to major hypoplasia of all four quadrants with varying degrees of herniation and areola enlargement.^{6,12,15,22} Many scientists have addressed the issue of this constricting ring (C. Gasperoni, personal communication, 1998),^{21,30} but no author has actually looked into its nature until very recently, when we performed

histological studies of the tissues involved in two of our most recent patients. Again, histology confirmed the existence of a band of dense connective tissue in the area.

Most surgeons acknowledge that merely placing an implant behind the deformed breast does not correct the problem, instead resulting in a double-bubble deformity.^{4,10,12,14,31} Failure to address the problem of the constricting ring is the main reason why the results yielded by most

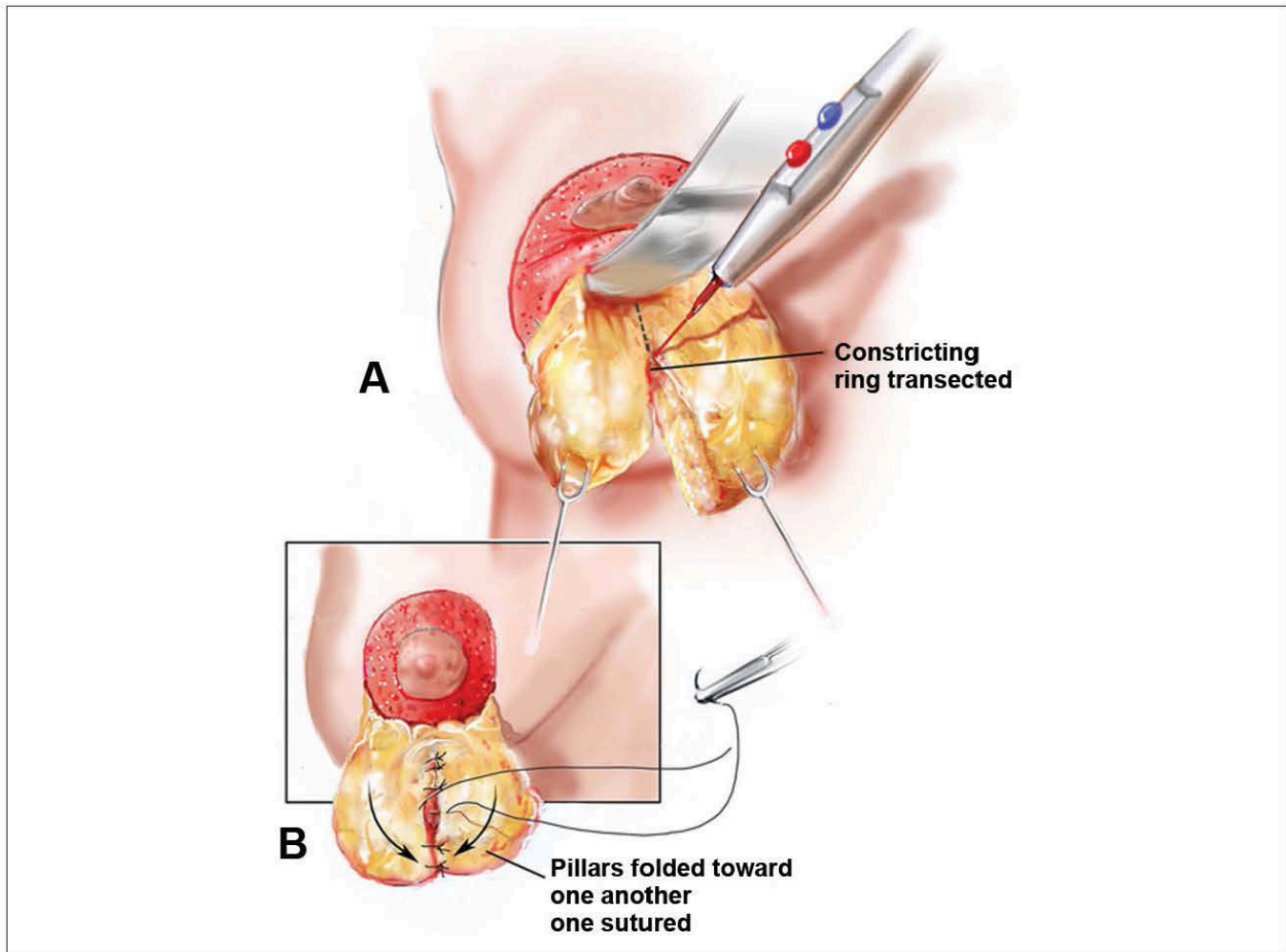


Figure 8. (A) By transecting the lower pole of the breast, the constricting ring is divided, resulting in two pillars. (B) The two pillars are brought together loosely in the six-o'clock position, where the transection took place, to avoid a gap.

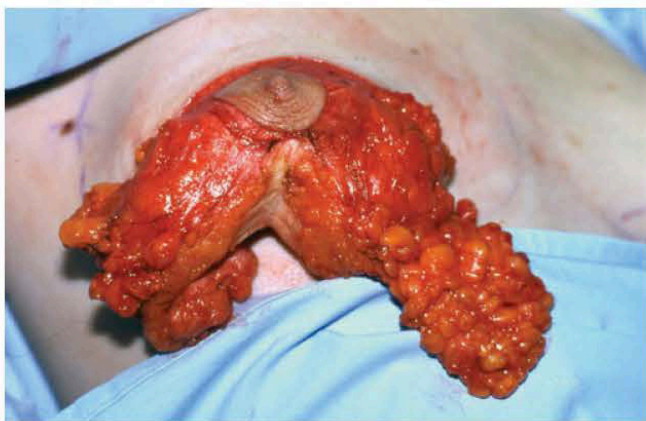


Figure 9. If the two pillars described in Figure 8 are long, the proximal parts should again be approximated with absorbable sutures. The distal parts are allowed to redrape freely or are folded over each other like a “double-breasted” jacket to manufacture added volume in the inferior portion of the breast, exactly where it was lacking initially.

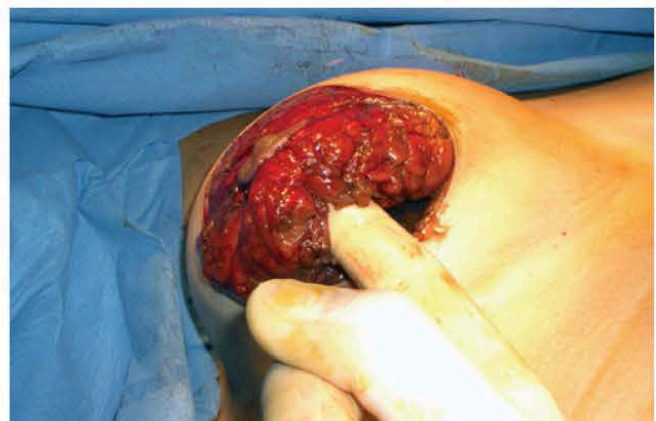

Figure 10. The two pillars are brought together loosely and sutured to avoid a gap.

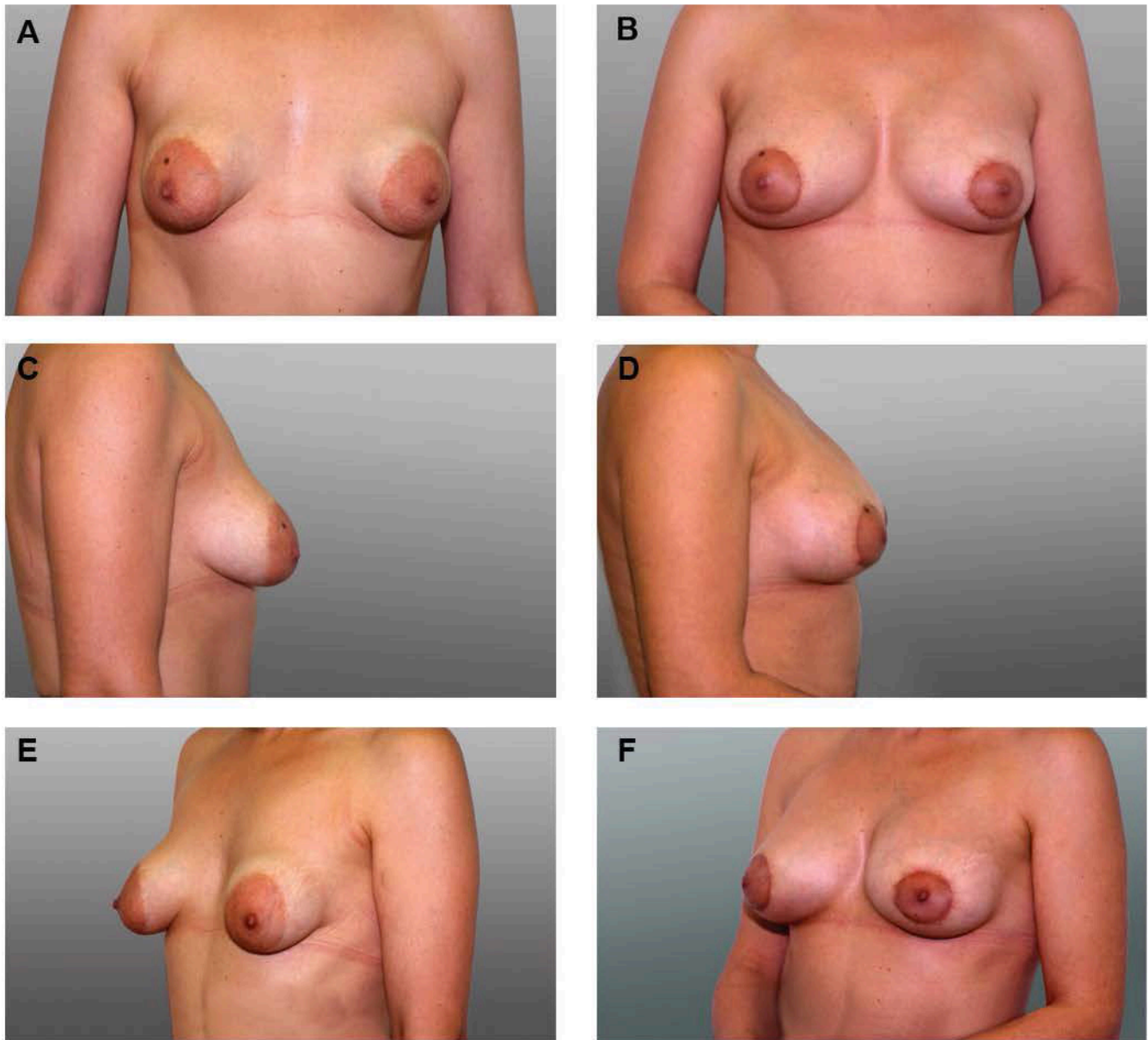


Figure 11. (A, C, E) This 46-year-old woman presented to our clinic with a previous failed attempt to reconstruct a bilateral type II tuberous breast deformity with subglandular placement of (110 cc) silicone breast implants. Both breasts were constricted in both the vertical and horizontal axis, with herniation of the breast parenchyma toward the nipple-areola complex and increased size of the areola. (B, D, F) Four months after a periareolar donut-type deepithelialization was followed by removal of the implants, capsulectomy, dissection of the breast parenchyma, division of the fibrous ring with development of two pillars, and placement of 275-cc implants in the same subglandular pocket.

methods are far from satisfactory. There are, however, some authors who have focused on this point and have attempted to rearrange the breast parenchyma to mold a more natural-looking breast. Rees and Aston⁴ were the first to propose radial incisions on the back of the breast to expand its base, but their technique did not actually transect the constricting ring. Dinner and Dowden¹³ realized that there was something constricting the breast in its inferior pole, but thought the skin was responsible for this constriction and employed a full-thickness incision through

skin, subcutaneous tissue, and breast to release it, followed by transposition of a skin and subcutaneous tissue flap. Other authors have sought to rearrange the inferior pole of the breast by transecting the breast parenchyma horizontally and then unfolding the flap inwards or outwards,^{5,21,32} but the results have not always been aesthetically pleasing.

Ribeiro's technique^{21,30,33} is similar to ours in principle. He transected the constricting ring in a horizontal axis and then developed a flap from the inferior portion of the

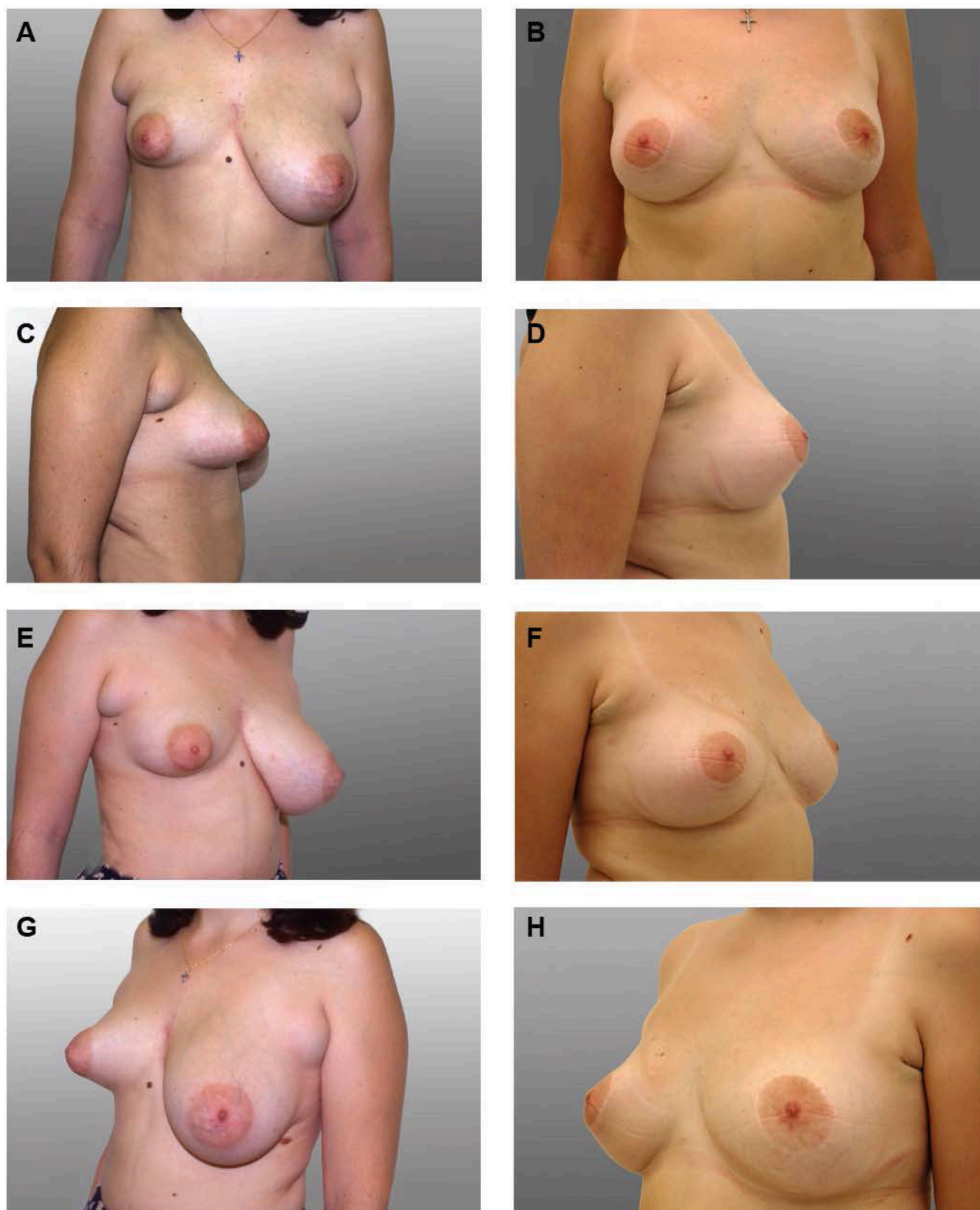


Figure 12. (A, C, E, G) This 23-year old woman presented with type II right tuberous breast deformity with hypoplasia of the inferior pole, herniation of the breast parenchyma toward the nipple-areolar complex, and moderately increased areolar diameter. The left breast is slightly large, with Regnault's class A ptosis. (B, D, F, H) One year after treatment of the right breast with a periareolar donut-type deepithelialization and readjustment of the breast parenchyma (without an implant) and the left breast with inferior pedicle-type breast reduction coupled with excision of the axillary tail of Spence bilaterally.

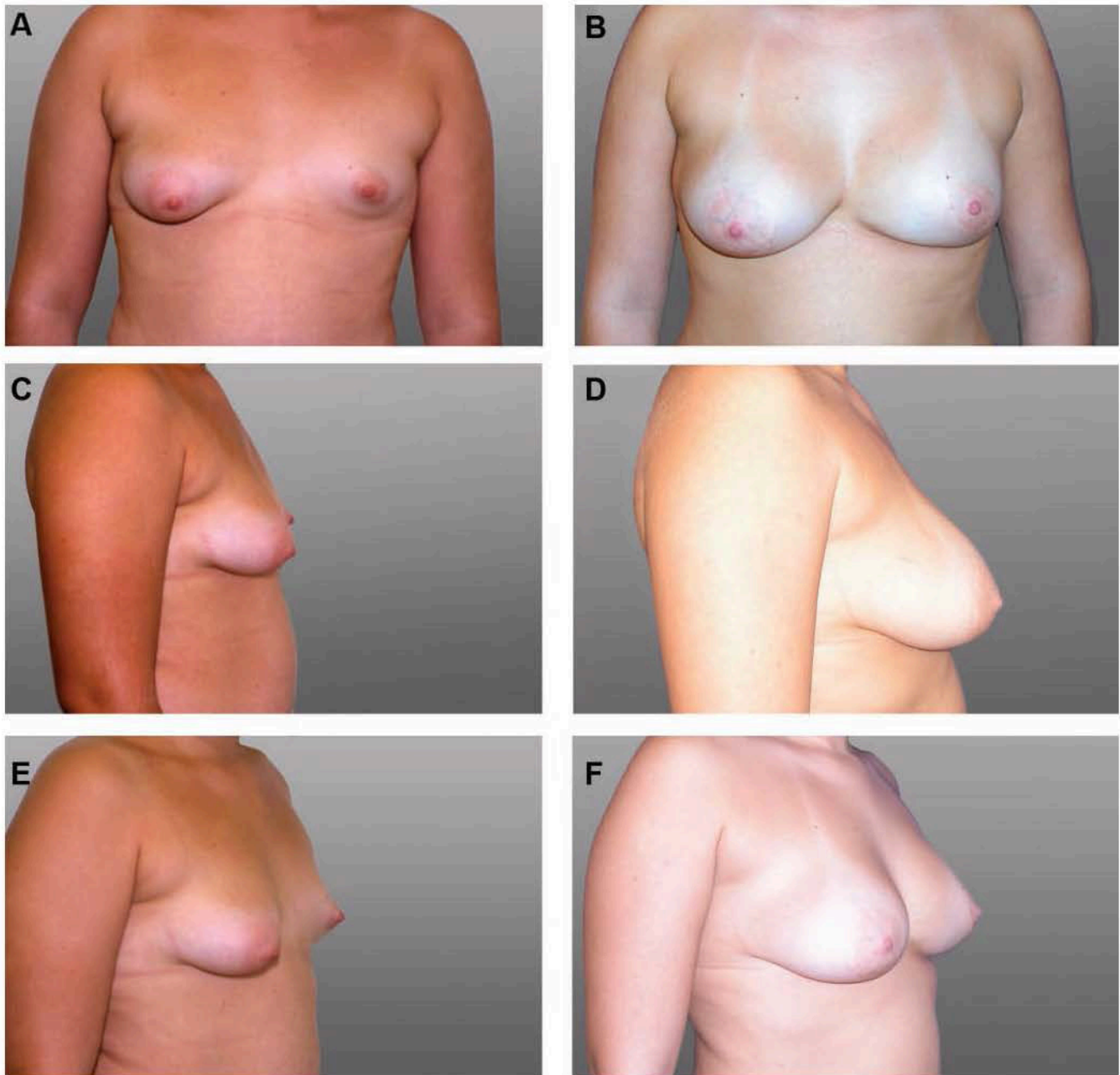


Figure 13. (A, C, E, G, I) This 17-year-old woman presented with bilateral asymmetrical tuberous breast deformity. The right breast was characterized by underdevelopment of the inferior pole (type II), whereas on the left side, there was severe hypoplasia of the whole breast (type III). (B, D, F, H, J) Four years after both breasts were treated with semicircular periareolar incision, readjustment of the breast parenchyma, and subglandular placement of silicone breast implants (right: 200 cc, left 300 cc).

breast to enhance the projection of the hypoplastic breast, doing away with implants, as his patients were not particularly concerned with large breast volumes. However, our approach is slightly different. The constricting ring is transected at the six o'clock semiaxis of the breast, thus defining two pillars in the inferior part of the breast. The pillars are then either loosely reapproximated with absorbable sutures or folded over each other in the fashion of a "double-breasted" jacket to add volume in the inferior

portion of the breast, with the optional addition of a breast implant underneath the breast or the pectoralis major muscle to correct any volume deficiency.

Other advantages of our technique include confinement of the scars to the periareolar margin; they are virtually invisible in most cases. Furthermore, our method does not disturb the lactiferous ducts, thus maintaining normal breast function (provided that adequate breast parenchyma was present before the procedure).

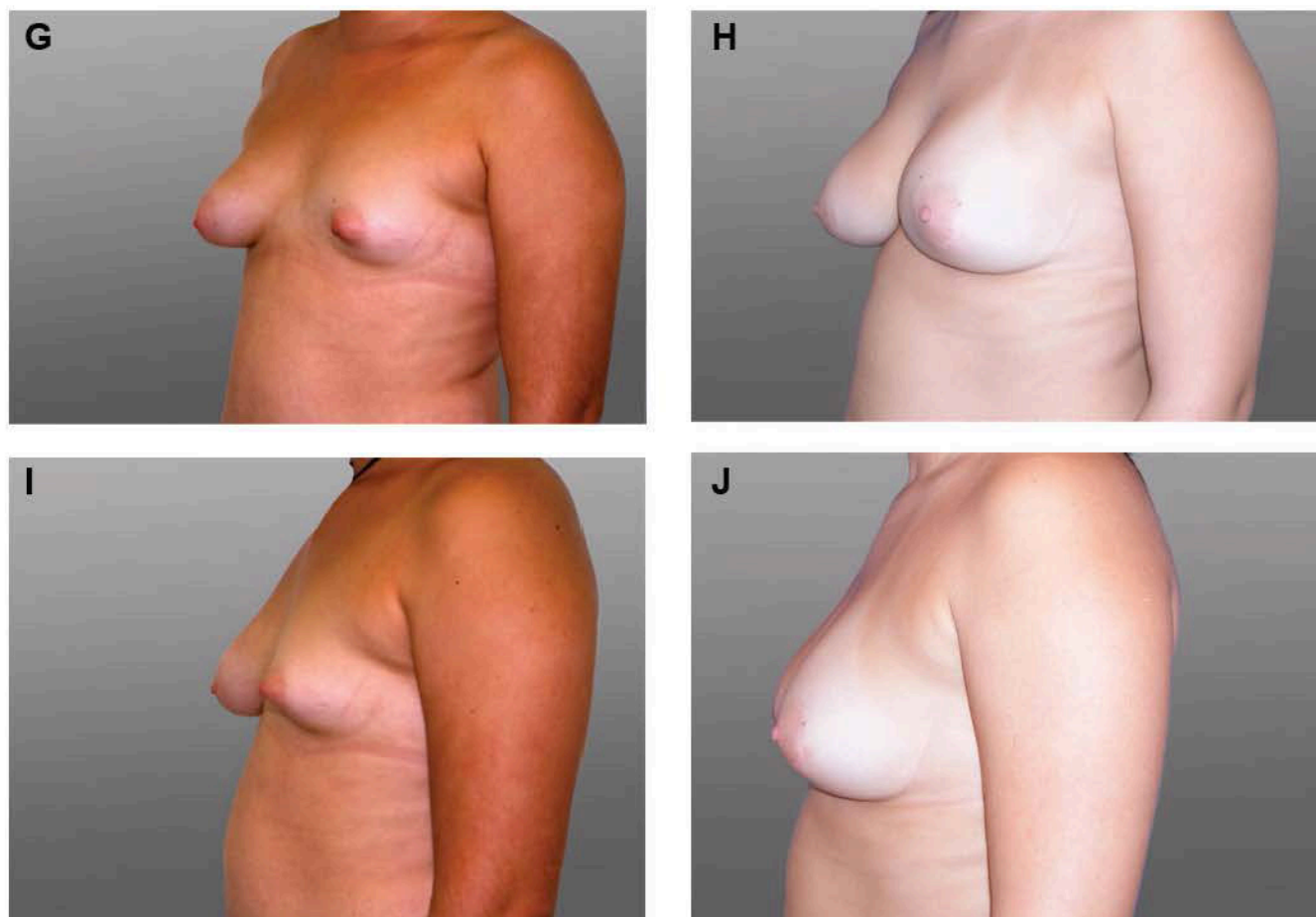


Figure 13. (continued) (A, C, E, G, I) This 17-year-old woman presented with bilateral asymmetrical tuberous breast deformity. The right breast was characterized by underdevelopment of the inferior pole (type II), whereas on the left side, there was severe hypoplasia of the whole breast (type III). (B, D, F, H, J) Four years after both breasts were treated with semicircular periareolar incision, readjustment of the breast parenchyma, and subglandular placement of silicone breast implants (right: 200 cc, left 300 cc)

Table 1. Complications

Type of Complication	Frequency	No. (%) in Our Series (n = 41 Breasts)	Comments
Bruising and swelling	+	41/41 (100)	Almost always occurs
Hematoma	+	1/41 (2.5)	Maintain meticulous hemostasis
Infection	-	0	Observe aseptic techniques
Skin flap necrosis	+	0	Avoid overthinning of the flap and apply electrocautery carefully
Altered nipple sensation	+	0	Avoid superolateral dissection
Capsular contracture	+	1/41	Same precautions as in breast augmentation
Malposition	-	0	Plan and execute dissection very carefully
Asymmetry	+/-	1	May demand surgery on contralateral breast
Persistent/residual lower pole constriction	-	0	Ensure that all constriction is eliminated and take care not to puncture the skin
Sensory loss at lower pole	-	0	
Rippling	-	0	
Palpability	-	0	

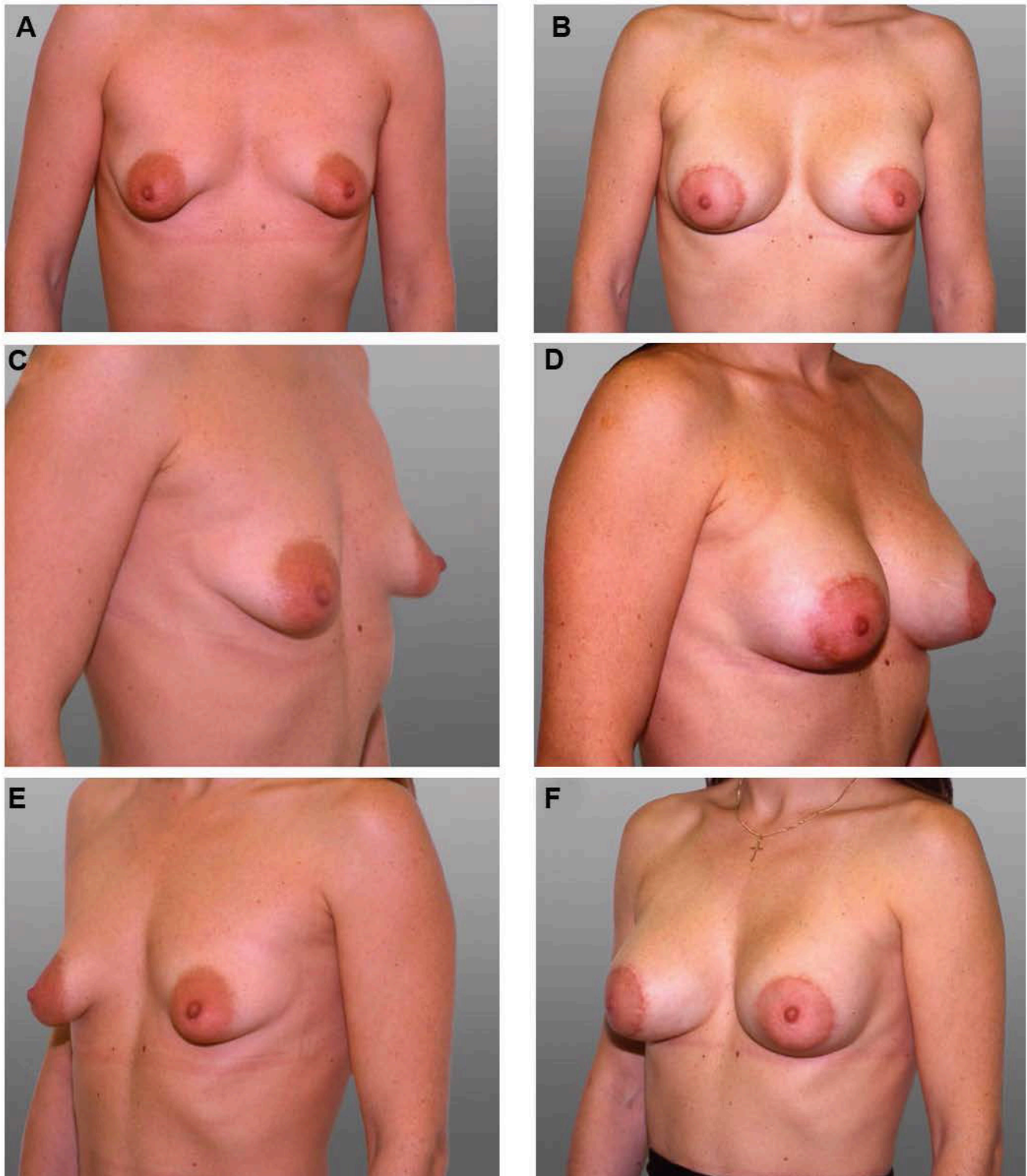


Figure 14. (A, C, E) This 30-year-old woman presented with bilateral type II tuberous breast deformity. The main features of the deformity were underdevelopment of the inferior pole of the breast, with slightly increased areolar diameter. (B, D, F) One year after treatment with a periareolar donut-type deepithelialization, followed by readjustment of the breast parenchyma and insertion of 225-cc silicone breast implants. (G, H, I) Three years postoperatively, when the patient was 20 weeks pregnant. (J, K) This patient also developed a postoperative hematoma on the right breast that had to be evacuated, which probably led to a Baker III capsular contracture on the same side, six years postoperatively.

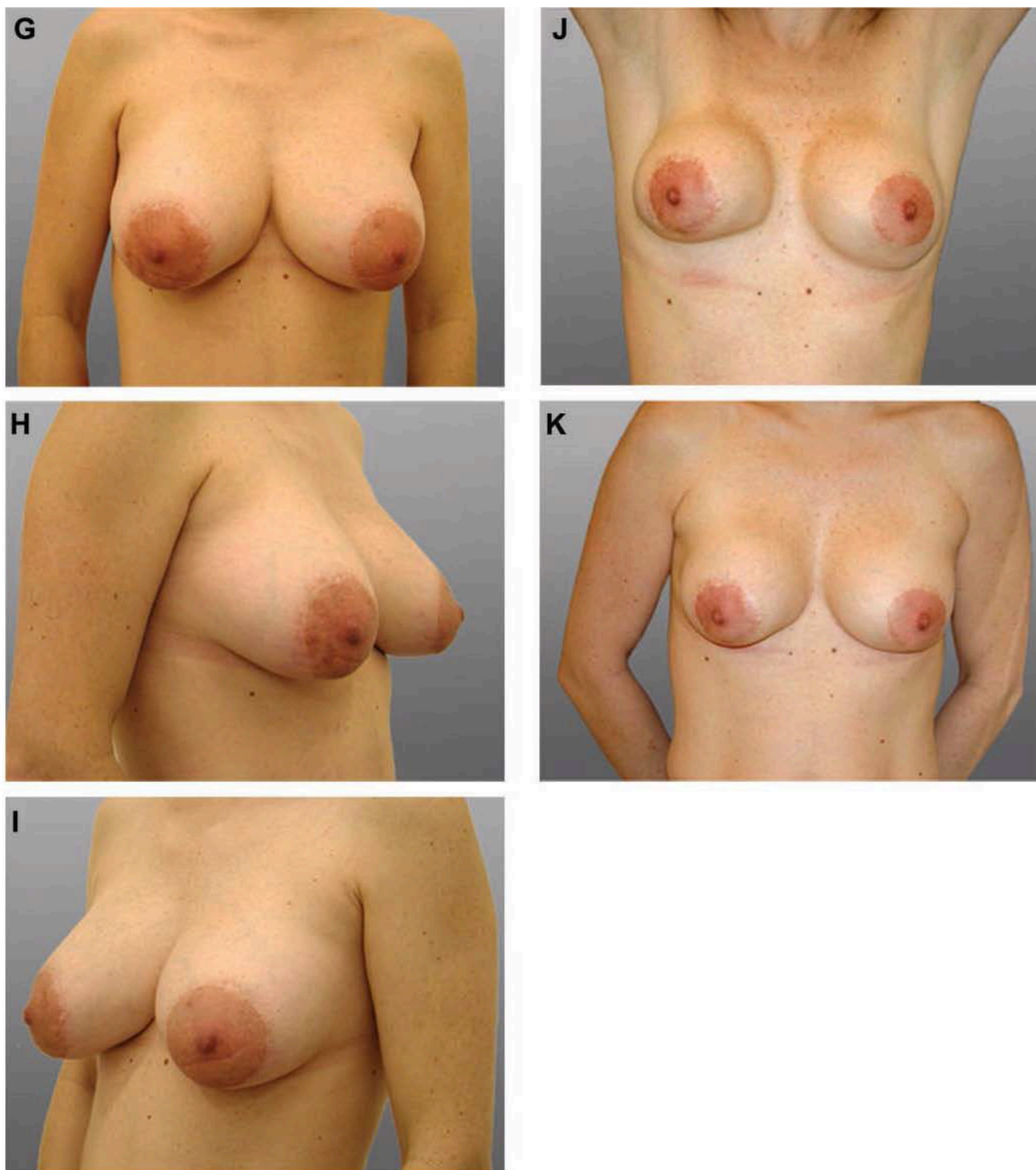


Figure 14. (continued) (A, C, E) This 30-year-old woman presented with bilateral type II tuberous breast deformity. The main features of the deformity were underdevelopment of the inferior pole of the breast, with slightly increased areolar diameter. (B, D, F) One year after treatment with a periareolar donut-type deepithelialization, followed by readjustment of the breast parenchyma and insertion of 225-cc silicone breast implants. (G, H, I) Three years postoperatively, when the patient was 20 weeks pregnant. (J, K) This patient also developed a postoperative hematoma on the right breast that had to be evacuated, which probably led to a Baker III capsular contracture on the same side, six years postoperatively

CONCLUSIONS

The authors propose a technique that is simple and yields consistently good results for the treatment of tuberous breast deformity. Patients who have been treated by the authors with this method over the past 10 years have experienced aesthetically pleasing postoperative results with few complications.

Disclosures

The authors declared no conflicts of interest with respect to the authorship and/or publication of this article.

Funding

The authors received no financial support for the research and/or authorship of this article.

REFERENCES

1. Toranto IR. Two-stage correction of tuberous breast. *Plast Reconstr Surg* 1981;67:642-646.
2. Atiyeh BS, Hashim HA, El-Douaihy Y, Kayle DI. Perinipple round-block technique for correction of tuberous/tubular breast deformity. *Aesthetic Plast Surg* 1998;22:284-288.
3. Zambacos GJ, Mandrekas AD. The incidence of tuberous breast deformity in asymmetric and symmetric mammoplasty patients. *Plast Reconstr Surg* 2006;118:1667-1668.
4. Rees TD, Aston SJ. The tuberous breast. *Clin Plast Surg* 1976;3:339-347.
5. Grolleau J-L, Lanfrey E, Lavigne B, Chavoin J-P, Costagliola M. Breast base anomalies: treatment strategy for tuberous breasts, minor deformities, and asymmetry. *Plast Reconstr Surg* 1999;104:2040-2048.
6. von Heimburg D, Exner K, Kruff S, Lemperle G. The tuberous breast deformity: classification and treatment. *Br J Plast Surg* 1996;49:339-345.
7. Gruber RP, Jines HW Jr. The "donut" mastopexy: indications and complications. *Plast Reconstr Surg* 1980;65:34-38.
8. Panettiere P, Del Gaudio G-A, Marchetti L, Accorsi D, Del Gaudio A. The tuberous breast syndrome. *Aesthetic Plast Surg* 2000;24:445-449.
9. Gasperoni C, Salgarello M, Gargani G. Tubular breast deformity: a new surgical approach. *Eur J Plast Surg* 1987;9:141-145.
10. Teimourian B, Adham MN. Surgical correction of the tuberous breast. *Ann Plast Surg* 1983;10:190-193.
11. Bruck HG. Hypoplasia of the lower medial quadrant of the breast. *Aesthetic Plast Surg* 1992;16:283-286.
12. Williams JE. Discussion: two-stage correction of tuberous breast. *Plast Reconstr Surg* 1981;67:647.
13. Dinner MI, Dowden RV. The tubular/tuberous breast syndrome. *Ann Plast Surg* 1987;19:414-420.
14. Scheepers JH, Quaba AA. Tissue expansion in the treatment of tubular breast deformity. *Br J Plast Surg* 1992;45:529-532.
15. Meara JG, Kolker A, Bartlett G, Theile R, Mutimer K, Holmes AD. Tuberous breast deformity: principles and practice. *Ann Plast Surg* 2000;45:607-611.
16. Hughes LE, Mansel RE, Webster DJT. Breast anatomy and physiology. In: Hughes LE, Mansel RE, Webster DJT, editors. *Benign Disorders and Diseases of the Breast: Concepts and Clinical Management*. London: Bailliere Tindall; 1989. p. 5-13.
17. Osborne MP. Breast development and anatomy. In: Harris JR, Hellman S, Henderson IC, Kinne DW, editors. *Breast Diseases*. 2nd ed. Philadelphia: Lippincott; 1991. p. 1-13.
18. Moore KL. The integumentary system. In: *The Developing Human: Clinically Oriented Embryology*. 4th ed. Philadelphia: WB Saunders; 1988. p. 426-428.
19. Bostwick J III. Anatomy and physiology. In: *Plastic and Reconstructive Breast Surgery*. 2nd ed. St. Louis, MO: Quality Medical Publishing; 2000. p. 89-93.
20. Mandrekas AD, Zambacos GJ, Anastasopoulos A, Hapsas D, Lambrinaki N, Ioannidou-Mouzaka L. Aesthetic reconstruction of the tuberous breast deformity. *Plast Reconstr Surg* 2003;112:1099-1108.
21. Ribeiro L, Canzi W, Buss A, Accorsi A Jr. Tuberous breast: a new approach. *Plast Reconstr Surg* 1998;101:42-50.
22. von Heimburg D. Refined version of the tuberous breast classification. *Plast Reconstr Surg* 2000;105:2269-2270.
23. Mandrekas AD, Zambacos GJ. Preoperative infiltration with lidocaine and epinephrine for breast reduction. *Plast Reconstr Surg* 1999;103:2087.
24. Elliott MP. A musculocutaneous transposition flap mammaplasty for correction of the tuberous breast. *Ann Plast Surg* 1988;20:153-157.
25. Wilkinson TS. Re: Elliott: Mammoplasty for the tuberous breast. *Ann Plast Surg* 1988;21:294.
26. Marchioni EE. Surgical treatment of tuberous breasts with bilateral mega-areola with a periareolar scar technique. *Ann Plast Surg* 1993;30:363.
27. Kneafsey B, Crawford DS, Khoo CTK, Saad MN. Correction of developmental breast abnormalities with a permanent expander/implant. *Br J Plast Surg* 1996;49:302-306.
28. Muti E. Personal approach to surgical correction of the extremely hypoplastic tuberous breast. *Aesthetic Plast Surg* 1996;20:385-390.
29. Argenta LC, VanderKolk C, Friedman RJ, Marks M. Refinements in reconstruction of congenital breast deformities. *Plast Reconstr Surg* 1985;76:73-80.
30. Ribeiro L, Accorsi A Jr, Buss A, Marcal-Pessoa MC. Short scar correction of the tuberous breast. *Clin Plast Surg* 2002;29:423-431.
31. de la Fuente A, Martin del Yerro JL. Periareolar mastopexy with mammary implants. *Aesthetic Plast Surg* 1992;16:337-341.
32. Puckett CL, Concannon MJ. Augmenting the narrow-based breast: the unfurling technique to prevent the double-bubble deformity. *Aesthetic Plast Surg* 1990;14:15-19.
33. Regnault P. Breast ptosis: definition and treatment. *Clin Plast Surg* 1973;3:193-203.