

The Distally Based Sural Flap: A Useful Tool in the Coverage of Complex Wounds of the Distal Third of Shin and Proximal Foot

Clinical Study

G.A. Spyropoulou, G.J. Zampakos, D. A. Hapsas, M. Kalofonou, S. Vourtsis, A. D. Mandrekas

Received 09/06/2011 Accepted 20/07/2011

Abstract

Aim-Background: The aim of this paper is to prove that the sural flap in the coverage of complex wounds of the distal third of shin and proximal foot is a safe and effective technique. Coverage of lower extremity defects can be troublesome to the Plastic Surgeon. Usually, these defects are treated with free flaps. However, microvascular reconstruction of leg wounds requires microsurgical expertise and increases operative time. The distally based sural flap offers an appealing alternative to microvascular reconstruction as it can be harvested in a short time without sacrificing a major vessel of the leg, and donor site morbidity is minimal.

Patients-Methods: We present our experience with the use of the sural flap in the coverage of complex wounds of the distal third of shin and proximal foot in 12 patients.

Results: All defects were covered successfully without major complications.

Conclusion: The distally based sural flap is a useful tool for small to moderate size defects of the lower one third of the leg, the foot and the heel.

Key words:

Sural flap, Fasciocutaneous flap, Complex wounds, Distal third of shin, Proximal foot

Introduction

Reconstruction of defects of the lower third of leg and proximal foot can be demanding. The plethora of vessels, nerves and tendons in close proximity to the skin and shortage of local tissue that could be used for coverage, represent a complicated equation for the Reconstructive Surgeon. Microvascular reconstruction offers great versatility and is probably the best alternative in similar cases. However, owing to local or systemic drawbacks, free tissue

transfer is not always an option. In such cases, Plastic Surgeons rely on local or regional flaps for reconstruction of lower extremity wounds.

Fasciocutaneous flaps, first defined by Pontén in 1981, were used for defects of the lower third of the leg [1]. The distally based sural fasciocutaneous flap was described in 1983 by Donski and Fogdestam [2]. The authors presented their experience in three clinical cases with a flap of distal pedicle based on perforators of the peroneal artery. However, a thorough description of the relevant anatomy of the sural flap is attributed to Masquelet et al. who demonstrated that there is a vascular network supplying blood to the skin, deriving from the arteries that follow the course of the superficial sensitive nerves [3].

Usually, the sural nerve runs between the two heads of gastrocnemius muscle and penetrates the deep fascia approximately at the middle of the leg. One to three arteries run along with the sural nerve. These arteries anastomose with the peroneal artery through septocutaneous perforators located in the posterior crural septum. The existence of the above-mentioned anastomoses allows the skin overlying the gastrocnemius muscle to be elevated as a reverse flap. The venous drainage of this flap is from the lesser saphenous vein that runs along the same axis as the sural nerve.

The aim of this paper is to prove that the sural flap in the coverage of complex wounds of the distal third of shin and proximal foot is a safe and effective technique.

Anatomy

The axial pattern blood flow of the reverse sural fasciocutaneous flap consists of the median superficial sural artery, which runs parallel with the medial sural cutaneous nerve, and the medial and lateral superficial sural arteries, so-named after their relationship to the two heads of the gastrocnemius muscle. Not all three superficial sural arteries are always present. The median superficial sural artery which is the largest of the three is present in 83 to 97 percent of specimens; the lateral superficial sural artery is present in 81 percent and the medial su-

G.A. Spyropoulou (Corresponding author), G.J. Zampakos, D. A. Hapsas, M. Kalofonou, S. Vourtsis, A. D. Mandrekas

- Artion Clinic, N. Psichiko, Athens, Greece

✉ e-mail: gspiropoulou@hotmail.com

perforial sural artery in 17 percent of specimens [4]. These arteries form an anastomotic network that supplies blood to the skin and fascia of the sural angiosome [5]. These axial pattern vessels anastomose with septocutaneous perforators from the peroneal artery that pass between the fibula and flexor hallucis longus proximally and between the fibula and peroneus longus distally to supply the skin of the lateral leg. The most distal of the peroneal perforators is located 4 to 7 cm proximal to the lateral malleolus. The sural angiosome is also supplied by septocutaneous perforators arising from the posterior tibial artery. These perforators pass between the tibia and soleus proximally and between the flexor digitorum longus and soleus distally [6]. Finally, the rich vascular network that supplies the suprafascial, subcutaneous and subdermal plexus of the sural angiosome is enhanced by perforators from the extrinsic vascular plexus that runs along the length of the sural nerve and lesser saphenous vein. Hence, inclusion of the sural nerve and lesser saphenous vein in the flap optimizes local blood flow.

Surgical Technique

Dissection of the distally based sural flap has been well described in prior publications [7, 8]. With the patient in the prone position, the tendinous intersection between the gastrocnemius muscles is identified. This approximately corresponds to the course of the sural nerve and lesser saphenous vein, and will be the central axis of the flap. The peroneal perforators are identified by Doppler ultrasonography along the posterior crural septum. The location of the most proximal perforator to the lateral malleolus roughly corresponds to the pivot point of the flap. Previous studies place the position of the pivot point at a distance of 10 to 1.5 cm from the lateral malleolus [9, 10]. However, most authors agree that the pivot point must be a minimum of 5cm proximal to the lateral malleolus [7, 8, 11]. Doppler examination is also used to locate the lesser saphenous vein and ensure inclusion of this structure in the flap.

The skin island is marked around the aforementioned central axis of the flap. The dimensions of the skin island should correspond to the size of the defect. The maximum size of the flap has been re-

Table 1 List of patients: Characteristics

Cas No	Age/sex	Nature of injury	Flap size	Comorbid conditions	Complications	Result	Follow-up (months)
1	76/F	MVA-trimalleolar fracture left-osteosynthesis	8x7	Diabetes The flap was tunnelled	Minor peripheral necrosis-treated with debridment	Fully healed	12
2	36/M	Osteomyelitis at the lower third of tibia	7x10	None	Venus stasis due to compressive bandage-improved when the bandages were removed	Fully healed	15
3	30/M	MVA-Fracture left lateral malleolus-osteosynthesis	4x5	Heavy smoker	Minor peripheral necrosis-treated with debridment	Fully healed	17
4	77/M	MVA-grade IIIB tibia-fibula fracture	7x4	CHF	None	Fully healed	8
5	23/M	Full thickness burn (friction) lateral malleolus right	5x4	None	None	Fully healed	15
6	27/M	MVA-skin avulsion right foot and skin and little toe avulsion left foot	15x10	None	None	Fully healed	18
7	28/M	Electrical burn dorsal surface left foot	8x10	None	None	Fully healed	6
8	67/M	Diabetic ulcer-osteomyelitis right heel	7x8	Diabetes	None	Fully healed	9
9	30/M	MVA-heel skin necrosis	17x16	None	None	Fully healed	16
10	25/F	MVA-soft tissue defect lateral foot right-exposure of lateral malleolus coverage with adipofascial sural flap	10x10	None	Minor marginal necrosis of the flap-was treated with debridement Minor peripheral necrosis-treated with debridment	Fully healed	10
11	50/M	MVA-fracture lateral malleolus left	8x7	Heavy smoker	Peripheral necrosis-treated with	Fully healed	17
12	37/M	Injection of cocaine dorsal surface right foot	12x10	Drug addict-heavy smoker	debridment and skin graft	Fully healed	5

ported as being from 12 to 23 cm in length and 8 to 16 cm in width [7, 9, 12-15].

Dissection of the flap starts at the cephalic margin. The lesser saphenous vein and sural nerve are identified and ligated. The deep fascia is incised and secured with temporary stitches to the skin in order to avoid damage of the delicate perforators from the extrinsic vascular plexus of the sural nerve and lesser saphenous vein towards the skin. The harvesting of the flap continues from proximal to distal at a plane below the deep fascia. The skin overlying the pedicle is elevated at a level above the superficial fascia. The width of the pedicle varies between 2 to 4 cm among authors [11, 16, 17]. Dissection of the pedicle continues until the flap can snugly reach the defect, and in no case further than 5 cm from the tip of the lateral malleolus. Once the width of the flap is less than 4 cm, the wound can be closed directly. Larger flaps would require a skin graft on the donor site.

Patients and methods

During the period February 2002 to July 2009, we treated 12 patients with the reverse sural flap (Table 1), of whom 2 were female and 10 were male with an age range from 23 to 77 years. Injuries were sustained by six patients involved in motor vehicle accidents (MVA): one patient was a harbour guard who had developed osteomyelitis as the result of an injury at work; one patient with diabetic ulcer; two patients had burns (one electrical and one friction burn) and one was a drug addict that had injected cocaine into the dorsal surface of his right foot. One flap was adipofascial (case no 10) and the rest were fasciocutaneous. In three cases the donor sites were closed directly (cases no 3, 5, and 6) while in the remaining cases the donor-site areas were covered with split-thickness skin grafts.

Results

Flap size ranged from 5x4 cm to 17x16 cm. A delay procedure was performed for 11 days in one patient (case no 8) with a diabetic ulcer. Average follow-up in this group was 12 months. All donor sites healed without any problem. Three flaps experienced minor peripheral necrosis that was treated with debridement and healed by secondary intention, and one flap presented with necrosis of an area of approximately 3 cm along the peripheral border that was treated with debridement and split thickness skin graft coverage. One flap (case no 2) experienced venous stasis in the first 5 hours postoperatively due to compressive dressing. The bandages were loosened

and venous stasis improved. At the end of follow-

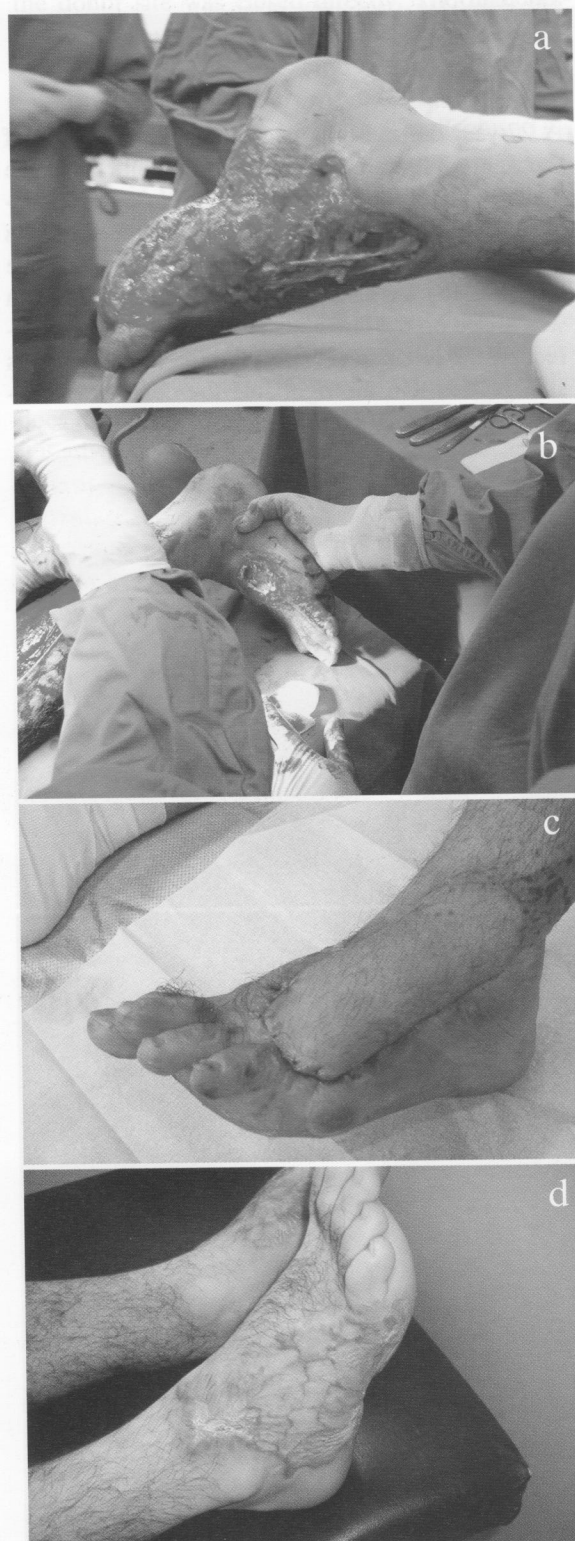

Fig. 1 1a: Skin Defect 20x10cm right lateral foot 1b: Skin defect and avulsion of the little toe left foot 1c: Coverage of the defect with split thickness skin graft 1d: Coverage of the defect with sural flap 5x5cm

up, all flaps were fully healed and all patients were ambulatory.

Examples case reports

Case 6

A 27-year-old man had sustained skin avulsion of the right foot laterally along with skin and slight toe avulsion of the left foot following an automobile-pedestrian accident. The resulting skin defect was 20x10cm on the right (Fig 1a) and 15x7cm on the left (Fig 1b). A distally based sural flap 15x10cm was raised on the left side. The flap covered the defect on the left side (Fig 1c) and the donor site was skin grafted. On the right side the defect was covered with a skin graft (Fig 1d).

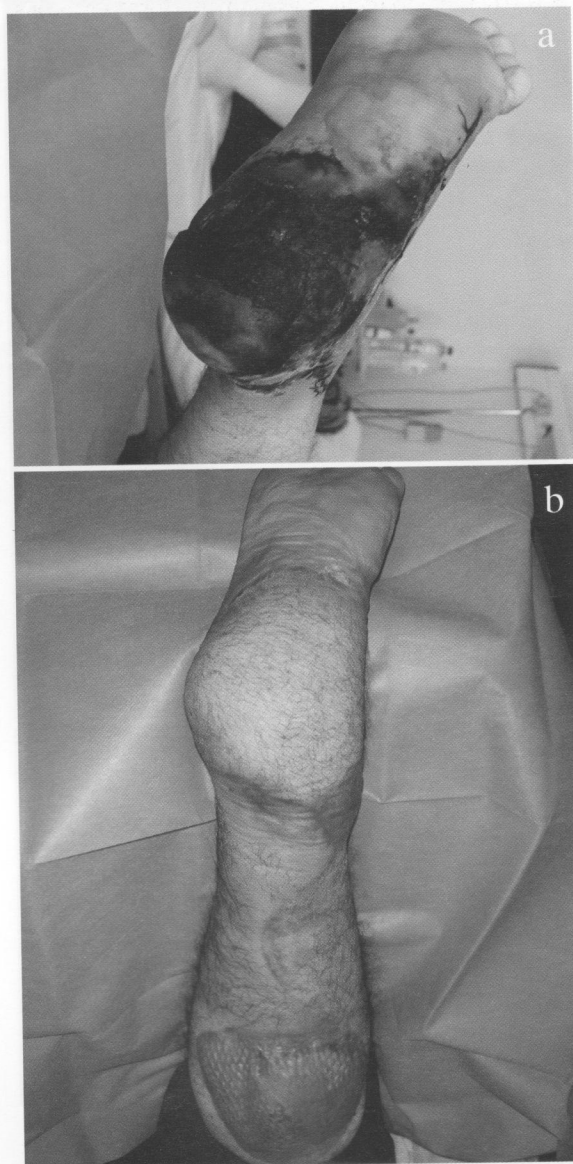


Fig. 2 2a: Necrosis of the whole heel skin up to the level of the metatarsals **2b:** Coverage with a supersural flap

Case 9

A 30-year-old patient was involved in a motor-vehicle accident. The heel skin was avulsed and subsequently necrosed up to the level of the metatarsals (Fig 2a). The wound was debrided and a supersural flap (17x16 cm) was designed. The proximal border of the flap was 1.5 cm distal to the popliteal crease. The flap was sutured onto the defect and the donor site was skin grafted. Both the donor and recipient area healed uneventfully (Fig 2b) and the patient was allowed to fully weight-bear 8 weeks post surgery.

Case 10

A 25-year-old lady sustained a motor-vehicle accident. The soft tissue defect involved the whole lateral side of the foot with exposure of the lateral malleolus (Fig 3a). The wound was debrided and a distally based sural flap (10x10cm) was designed. Since the patient was concerned about her appearance, the sural flap was raised as an adipofascial flap and the donor site was closed directly. The adipofascial flap was then covered with a split thickness skin graft. The donor site developed small marginal necrosis that was treated with debridement. The final contour of the foot and aesthetic result was satisfying to both the patient and physician (Fig 3b).

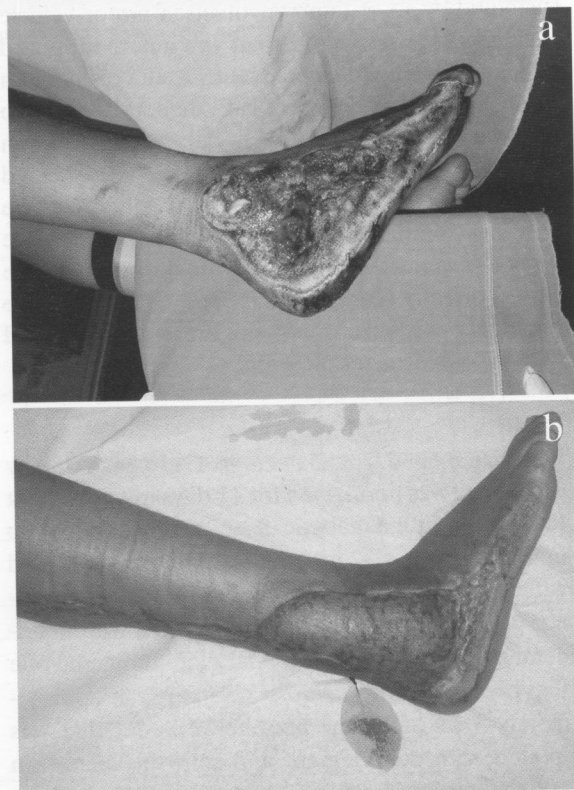


Fig. 3 3a: Soft tissue defect of the whole lateral side of the right foot with exposure of the lateral malleolus **3b:** The final contour of the foot was satisfying to both the patient and physician

Discussion

Several techniques have been described for the reconstruction of defects of the distal leg and foot. The inferiorly based soleus muscle flap is a risky option due to its variable vascular anatomy [18]. Other flaps that have been described such as the peroneal artery flap [19], the anterior tibial artery flap [20] and the posterior tibial artery flap [21] have the disadvantage of sacrificing a major artery to the foot. Microsurgery is probably the best option as it offers great versatility and reliable single stage coverage of wounds of the distal leg and foot. Nevertheless, there are several disadvantages to using microvascular reconstruction such as increased operating time, use of special equipment and microsurgical expertise [8,23]. Pedicled fasciocutaneous flaps for the reconstruction of analogous defects were first described by Ponten. However, the use of these flaps evolved from studies which demonstrated the irrigation of the skin from arteries that follow the course of lower limb nerves. The research of vascularised nerve grafts demonstrated that the skin of these nerve territories could be elevated based on the blood supply from the arteries emerging from the extrinsic vascular plexus of the aforementioned nerves [24,25]. Perhaps the most used of the fasciocutaneous flaps of the leg is the sural flap. The anatomic knowledge regarding this flap first improved with the work of Masquelet et al., and later with the angiographic studies of Nakajima et al [3, 26]. This flap offers versatility as it can be used as fasciocutaneous or adipofascial flap and reconstruction of the weight-bearing surface of the foot can be achieved with a sensate sural flap [11]. In our series, the flap was used in a variety of wounds of the distal leg and foot. In four patients, the flap was utilised in cases of complex fractures and covered internal fixation metalwork. The sural flap obliterated dead space and prevented infection. No cases of osteomyelitis or infection were reported. Two of these patients had comorbidities and were over 75 years of age. Hence, the risk from a microvascular lengthy operation would be increased. The time required for reconstruction with the sural flap was approximately 2.5 hours, which is significantly shorter than that required for free flap reconstruction. In one case, the sural flap was used for coverage of the whole plantar surface of the leg and in another case it was used for reconstruction of the dorsal surface of the foot in a drug addict who exhibited poor cooperation. Both of these patients refused the option of free flap reconstruction.

In one case (no 10), the patient was preoccupied with her appearance. In order not to use a skin graft,

the sural flap was raised as an adipofascial flap and the donor site was closed directly. The final aesthetic result was acceptable to the patient, and no debulking procedure was required.

In case no 12, the defect extended laterally up to the anterior border of the lateral malleolus. This was probably the cause of peripheral necrosis of the sural flap in this case. As mentioned by other authors, wounds that extend laterally may compromise some of the perforators as these would be within the zone of injury [8]. In all cases, mobilization of the pedicle was the minimum required to achieve adequate rotation. It is acknowledged that the possible presence of perforators originating far distally does not allow the flap to safely rely on those, and it is advisable to include as many perforators as possible at the base of the flap [4].

In these series, all flaps were successful, and at the end of follow-up, all patients were ambulatory with no bother from the donor site. The indications included exposure of noble structures or osteosynthesis material. In all cases the use of the sural flap provided stable coverage.

In summary, the sural fasciocutaneous flap allows reliable single-stage reconstruction of defects of the distal leg and foot. Major advantages of the sural flap lie in the easy and quick dissection and its simple design. The disadvantages include sacrifice of the sural nerve and the need for skin grafting of the donor site. Furthermore, the sural flap has size limitations and its use in distal defects is restricted by the position of the pivot point. Consequently, in larger flaps we should consider delay and supercharging procedures to avoid complications [4]. Finally, inclusion in the pedicle of as many peroneal artery perforators as possible and of the lesser saphenous vein optimizes the blood supply to the flap.

Conflict of interest

The authors declare that they have no conflict of interest.

References

1. Pontén B. The fasciocutaneous flap: its use in soft tissue defects of the lower leg. *Br. J. Plast Surg.* 1981; 34: 215-20.
2. Donski PK, and Fogdestam I. Distally based fasciocutaneous flap from the sural region: a preliminary report. *Scand. J. Plast. Reconstr. Surg.* 1983; 17: 191-6.
3. Masquelet AC, Romana MC, and Wolf G. Skin island flaps supplied by the vascular axis of the sensitive superficial nerves: Anatomic study and clinical experience. *Plast. Reconstr. Surg.* 1992; 89: 1115-21.
4. Follmar KE, Baccarani A, Baumeister SP, Levin LS, Erdmann D. The distally based sural flap. *Plast Reconstr. Surg.* 2007; 119: 138e-148e.
5. Taylor GI, and Pan WR. Angiosomes of the leg: Anatomic

- study and clinical implications. *Plast. Reconstr. Surg.* 1998, 102: 599-616; discussion 617-8.
6. Le Huec JC, Midy D, Chauveaux D. et al. Anatomic basis of the sural fascio-cutaneous flap: Surgical applications. *Surg. Radiol. Anat.* 1988, 10:5-13.
 7. Hasegawa M, Torii S, Katoh H, and Esaki S. The distally based superficial sural artery flap. *Plast. Reconstr. Surg.* 1994, 93: 1012-20.
 8. Hollier L, Sharma S, Babigumira E, and Klebuc M. Versatility of the sural fasciocutaneous flap in the coverage of lower extremity wounds. *Plast. Reconstr. Surg.* 2002, 110: 1673-9.
 9. Bocchi A, Merelli S, Morellini A, et al. Reverse fasciocutaneous flap versus distally pedicled sural island flap: Two elective methods for distal-third leg reconstruction. *Ann. Plast. Surg.* 2000, 45: 284-91.
 10. Zhang FH, Chang SM, Lin SQ, et al. Modified distally based sural neuro-veno-fasciocutaneous flap: Anatomical study and clinical applications. *Microsurgery* 2005, 25: 543-50.
 11. Jeng S, and Wei F. Distally based sural island flap for foot and ankle reconstruction. *Plast. Reconstr. Surg.* 1997, 99: 744-50.
 12. Jeng SF, Wei F, and Kuo Y. Salvage of the distal foot using the distally based sural island flap. *Ann. Plast. Surg.* 1999, 43: 499-505.
 13. Yilmaz M, Karatas O, and Barutcu A. The distally based superficial sural artery island flap: Clinical experiences and modifications. *Plast. Reconstr. Surg.* 1998, 102: 2358-67.
 14. Rajacic N, Darweesh M, Jayakrishnan K, et al. The distally based superficial sural flap for reconstruction of the lower leg and foot. *Br. J. Plast. Surg.* 1996, 49: 383-9.
 15. Ayyappan T, and Chadha A. Super sural neurofasciocutaneous flaps in acute traumatic heel reconstructions. *Plast. Reconstr. Surg.* 2002, 109: 2307-13.
 16. Almeida MF, Costa PR, Okawa RY. Reverse-flow island sural flap. *Plast. Reconstr. Surg.* 2002, 109: 583-91.
 17. Fraccalvieri M, Verna G, Dolcet M, Fava R, Rivarossa A, Robotti E, Bruschi S. The distally based superficial sural flap: our experience in reconstructing the lower leg and foot. *Ann. Plast. Surg.* 2000, 45: 132-9.
 18. Townsend PLG. An inferiorly based soleus muscle flap. *Br. J. Plast. Surg.* 1978, 31: 210-3.
 19. Yoshimura M, Imura S, Shimamura K, et al. Peroneal flap for reconstruction in the extremity: Preliminary report. *Plast. Reconstr. Surg.* 1984, 74: 402-9.
 20. Wee JTK. Reconstruction of the lower leg and foot with the reverse pedicled anterior tibial flap: Preliminary report of a new fasciocutaneous flap. *Br. J. Plast. Surg.* 1986, 39: 327-37.
 21. Hong G, Steffens K, and Wang FB. Reconstruction of the lower leg and foot with the reverse pedicled posterior tibial fasciocutaneous flap. *Br. J. Plast. Surg.* 1989, 42: 512-6.
 22. Hollier L, Sharma S, Babigumira E, and Klebuc M. Versatility of the sural fasciocutaneous flap in the coverage of lower extremity wounds. *Plast. Reconstr. Surg.* 2002, 110: 1673-9.
 23. Goldberg JA, Adkins P, and Tsai TM. Microvascular reconstruction of the foot: Weight-bearing patterns, gait analysis, and long-term follow-up. *Plast. Reconstr. Surg.* 1993, 92: 904-11.
 24. Breidenbach WC, and Terzis JK. The anatomy of free vascularised nerve grafts. *Clin. Plast. Surg.* 1984, 11: 65.
 25. Gilbert A. Vascularised sural nerve graft. *Clin. Plast. Surg.* 1984, 11: 73-7.
 26. Nakajima H, Imanishi N, Fukuzumi S, et al. Accompanying arteries of the lesser saphenous vein and sural nerve: Anatomic study and its clinical applications. *Plast. Reconstr. Surg.* 1999, 103: 104-20.

Ανάστροφος Δερμοπεριτονιακός Κρημνός της Γαστροκνημίας: Ένα Χρήσιμο Εργαλείο στην Κάλυψη Επιπλεγμένων Τραυμάτων του Άνω Τριτημορίου της Κνήμης και του Εγγύς Ακρου Ποδός

Κλινική Μελέτη

Γ. Α. Σπυροπούλου, Γ. Ζαμπάκος, Δ. Χάψας, Μ. Καλωφόνου, Σ. Βούρτσης, Α. Μανδρέκας

Περίληψη

Η κάλυψη των ελλειμμάτων του κάτω τριτημορίου της κνήμης και τους εγγύς τμήματος του άκρου ποδός αποτελεί ένα δύσκολο πρόβλημα για τον Πλαστικό Χειρουργό λόγω της ένδειας δέρματος και μαλακών μορίων της περιοχής.

Συνήθως οι περιοχές αυτές καλύπτονται με ελεύθερους κρημούς. Το μειονέκτημα της χρήσης μικροχειρουργικών τεχνικών για αποκατάσταση αυτών των ελλειμμάτων είναι ότι απαιτούν εξειδίκευση και παρατείνουν τον εγχειρητικό χρόνο. Ο ανάστροφος δερμοπεριτονιακός κρημνός της γαστροκνημίας αποτελεί μια χρήσιμη εναλλακτική λύση καθώς μπορεί να ανασπασθεί σε μικρό χρόνο, με μικρή νοσηρότητα από τη δότρια και χωρίς να θυσιάσουμε κάποιο μείζον αγγείο.

Παρουσιάζουμε την εμπειρία μας με τη χρήση του ανάστροφου δερμοπεριτονιακού κρημού της γαστροκνημίας για κάλυψη επιπλεγμένων τραυμάτων του άνω τριτημορίου της γαστροκνημίας και του εγγύς τμήματος του άκρου ποδός σε 12 ασθενείς. Όλα τα ελλείμματα καλύφθηκαν με επιτυχία και χωρίς μείζονες επιπλοκές. Συμπερασματικά, ο ανάστροφος δερμοπεριτονιακός κρημνός της γαστροκνημίας αποτελεί μια δελεαστική επιλογή για κάλυψη μικρών έως μετρίου μεγέθους ελλειμμάτων του κάτω τριτημορίου της κνήμης, της πτέρνης και του εγγύς τμήματος του άκρου ποδός.

Λέξεις κλειδιά

Γαστροκνημιαίος κρημνός, Δερμοπεριτονιακός κρημνός, Ανάστροφος κρημνός